

Laparoscopic Gastric Bypass Surgery: Current Technique*

**PHILIP R. SCHAUER, MD,¹ SAYEED IKRAMUDDIN, MD,² GISELLE HAMAD, MD,¹
 GEORGE M. EID, MD,¹ SAMER MATTAR, MD,¹ DAN COTTAM, MD,¹
 RAMESH RAMANATHAN, MD,¹ and WILLIAM GOURASH, CRNP¹**

INTRODUCTION

THE TECHNIQUE OF LAPAROSCOPIC Roux-en-Y gastric bypass has evolved significantly since Wittgrove and Clark developed their technique in the early 1990s.¹ Multiple variations of each key aspect of the procedure have evolved.²⁻⁸ The major steps of the procedure include patient positioning, setup and port placement, pouch creation, Roux-limb construction, jejunum-jejunostomy, and gastrojejunostomy. Table 1 lists the multiple variations of each major step along with their advantages and disadvantages. The most complex step of the procedure is the gastrojejunostomy, which correspondingly varies most from surgeon to surgeon.

Our approach to the laparoscopic Roux-en-Y gastric bypass at the University of Pittsburgh has also evolved since we began our laparoscopic bariatric program in July of 1997. Our goal has been simplification of the procedure to reduce technical complications, facilitate teaching it to our fellows, residents, and visiting surgeons, and complete each case consistently within 1.5 to 2.5 hours. Our current experience as of January 2003 is approximately 2000 cases, and we have taught the procedure to more than 500 surgeons, including residents and fellows. In our first technique (cases 1-150), adapted from the method of Wittgrove and Clark, we created a retrocolic, retrogastric Roux-limb and used a circular stapler for the gastrojejunal anastomosis. The anvil was placed within the gastric pouch by passing it through the mouth with a pull wire technique. This method worked quite well, but we found that by using a linear stapler (cases 151-850) for the gastrojejunal anastomosis, as described by Champion et al.,³ we could simplify the procedure significantly. With the linear stapler, we observed a reduction (from 3% to less than 1%) in the rate of wound infections related to withdrawal of the contaminated circular stapler through the port site. We also achieved a 15- to 30-minute reduction in operating time with the linear stapler. In our

most recent modification (cases 851-2000), we switched from a retrocolic, retrogastric Roux-limb to an antecolic, antegastric Roux-limb, as described by Gagner et al.⁴ This modification has resulted in a significant reduction in the number of internal hernias caused by protrusion of the bowel through the mesocolon defect required in the retrocolic technique. Furthermore, we have not seen an increase in the number of complications resulting from the increased tension at the gastrojejunal anastomosis that is required with an antecolic Roux-limb. Thus, our current technique, which we describe and illustrate in this article, involves the following: a 15-mL gastric pouch; a two-layer gastrojejunal anastomosis (sutured outer layer and stapled inner layer); an antecolic, antegastric Roux-limb; and an end-side (stapled) jejunum-jejunostomy.

MINIMALLY INVASIVE OPERATING ROOM

Laparoscopic Roux-en-Y gastric bypass is a complex operation that is performed on complex, severely obese patients. Specialized operating rooms, such as the one shown in Figure 1, along with advanced surgical instruments and equipment, can significantly aid the surgeon in completing these procedures laparoscopically. The main features of the advanced operating room include high-quality optics with three-chip cameras (Stryker Endoscopy), high-quality monitors (Sony), voice activation of all controls (HERMES; Computer Motion, and Stryker Endoscopy), equipment booms to allow easy access to instruments and controls (Bercholdt), and an operating table suitable for patients weighing up to 800 lb (Skytron). The multiple high-quality monitors provide the surgeon with access to a variety of image inputs from the laparoscope, overhead camera, flexible endoscopes, ultrasonographic probes, digital x-rays, Internet images, and the patient's electronic medical record. Built-in com-

*This paper was modified in part from Schauer P: Laparoscopic Roux-en-Y Gastric Bypass at the University of Pittsburgh: Evolution of Technique. *Operative Techniques in General Surgery* 2003;5:114-124.

¹Department of Surgery, University of Pittsburgh, Pennsylvania, ²Department of Surgery, University of Minnesota.

TABLE 1. LAPAROSCOPIC ROUX-EN-Y GASTRIC BYPASS: VARIATIONS IN TECHNIQUE

<i>Operative technique</i>	<i>Description</i>	<i>Potential advantages</i>	<i>Potential disadvantages</i>
Patient position			
Supine, legs apart	Surgeon between legs	Surgeon preference	Longer setup time, possible pressure injury
Supine, legs together	Surgeon on right side	Easy setup	None
Operation sequence			
Foregut-midgut-foregut	Pouch, Roux, J-J, G-J	Allows earlier assessment of pouch and earlier conversion	More position changes
Midgut-foregut	Roux, J-J, pouch, G-J	Fewer table position changes, quicker	May delay conversion if required
Pouch creation			
<15 mL	Isolated, small pouch	Better weight loss, decreased GERD	More difficult G-J, increased tension on G-J
15–30 mL vertical	Slightly longer, larger pouch	Easier G-J, less tension on G-J	Less weight loss; increased GERD
Gastrojejunostomy			
Stapled			
Circular, transesophageal	Anvil passed down esophagus	Small pouch, small and constant stoma	Potential esophageal injury during anvil passage
Circular, transabdominal	Anvil passed through abdominal wall	Avoids esophageal passage	EEA stapler requires large opening in abdominal wall and risks infection
Linear, end-side	Endo-GIA for anastomosis, suture for enterotomy closure (or stapler)	Avoids EEA stapler and large opening in skin and reduces infection	Stoma size less likely uniform, requires some suturing
Hand-sewn	Constructed with suture only	Reduced cost	Suturing skill required, longer operative time
Banded outlet	Silastic or Marlex band reinforced outlet	May enhance long-term weight loss	Band may erode into lumen and require removal
Roux-limb construction			
Length	75 cm: standard 150–250 cm: long-limb	Enhanced weight loss with longer Roux	Smaller jejunal lumen with longer Roux, may increase risk for J-J stenosis
Orientation			
Retrocolic, retrogastric	Passes through mesocolon defect below colon and stomach	Less tension on G-J	Higher risk for internal hernia, must close mesocolon defect
Antecolic, antegastric	Passes anterior to colon and stomach, no mesocolon defect	No mesocolon defect, reduced risk for internal hernia	Increased risk for tension on G-J
Jejunostomy			
Stapled	Endo-GIA stapler for anastomosis and enterotomy closure	Stapled closure faster	Higher risk of stenosis
Stapled plus hand-sewn	Endo-GIA for anastomosis but enterotomy closed with suture	Hand-sewn enterotomy closure lower risk for stenosis	Increased operating time

EEA, end-to-end anastomosis; GERD, gastroesophageal reflux disease; GIA, gastrointestinal anastomosis; G-J, gastrojejunostomy; J-J, jejunostomy.

munications technology allows two-way live audiovisual communication to specialty services such as radiology and pathology. For teaching purposes, images can be broadcast locally, regionally, and internationally.

INSTRUMENTS FOR LAPAROSCOPIC ROUX-EN-Y GASTRIC BYPASS

Many specialized instruments make laparoscopic gastric bypass feasible (Fig. 2). A high-quality three-chip

camera (Stryker Endoscopy) and a 10-mm, 45-degree laparoscope are critical to obtaining a clear, bright image. Extra-long (55 cm) scopes, trocars, and instruments are available for these super-obese patients. Trocars that provide a tight seal and allow the use of instruments with multiple diameters are essential. A variety of grasping instruments enable delicate and firm handling of tissue. Endoscopic stapling devices such as the Endo-GIA (US Surgical Corporation, Norwalk, Connecticut) are absolutely essential for laparoscopic gastric bypass. A variety of cartridges with multiple staple heights (2.0, 2.5, 3.5, and 4.8

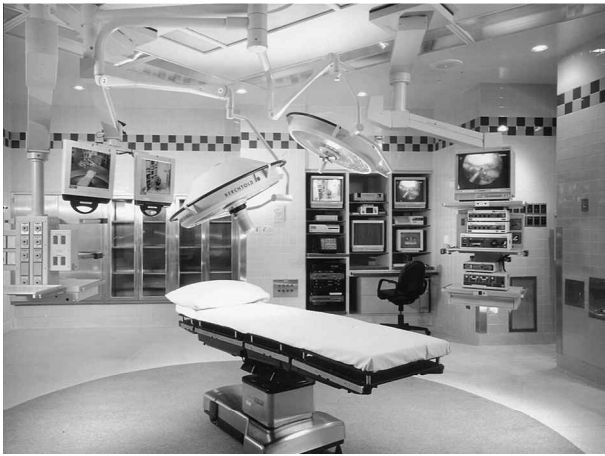

FIG. 1. Univeristy of Pittsburgh Minimally Invasive Operating Theatre.

mm) and cartridge lengths (30, 45, and 60 mm) are available. Reticulating cartridges are sometimes helpful when acute angles are required.

OVERVIEW OF TECHNIQUE

An overview of the University of Pittsburgh technique of laparoscopic Roux-en-Y gastric bypass with a list of the seven major steps is shown in Figure 3. The procedure involves the creation of a 15-mL stapled gastric pouch, a two-layer end-side gastrojejunostomy (inside staples and outside sutures), a 75- to 150-cm antecolic, antegastric Roux-limb, and a stapled end-side jejunajejunostomy. The sequence of steps in a laparoscopic Roux-en-Y gastric bypass can be quite variable. Our preference is to begin with creation of the Roux-limb, followed by the jejunajejunostomy, and to end with the gastrojejunostomy. This sequence allows us to begin with the patient in a supine position and end with the patient in a reverse Trendelenburg position, so that only one position change is required during the operation. Secondly, it allows us to begin in the midgut and progress logically to the foregut, with minimal back-and-forth movements.

Set-up and positioning

The patient is placed supine on an operating table capable of securely holding someone who may weigh up to 800 lb (Fig. 4) and is strapped in above and below the waist. After the induction of general anesthesia and endotracheal intubation, a bladder catheter is inserted, then sequential compression devices are placed around the lower extremities to prevent intraoperative venous thrombosis. An orogastric tube (18F) is temporarily placed to decompress the stomach. (Removal before gastric sta-

pling is required!) Care is taken to ensure that excessive pressure is not applied to any parts of the limbs or torso to avoid pressure injuries sustained after a lengthy procedure. Intravenous access via the upper extremity is usually sufficient. Occasionally, central access via the internal jugular or subclavian vein is necessary for monitoring. The monitors with the associated equipment (camera box, light source, insufflator) are placed above the patient's shoulders on each side and aimed at the surgical team. The skin is prepared with an antibacterial solution such as Betadine from the breasts to the pubis, including the far right and left flanks. Drapes are placed to cover the torso and limbs, excluding the abdominal skin. The personnel are positioned as shown. We prefer that the surgeon stand on the right side (as in open surgery) rather than between the patient's legs, as some surgeons prefer. This position appears more comfortable for the surgeon (and patient) and is less cumbersome to set up. A robotic camera holder such as the AESOP (Computer Motion) may be substituted for the camera person (see next figure) and may provide superior laparoscope image control and sturdiness. The camera, laparoscope, light cord, and insufflation tubing are all positioned onto the surgical field, and the camera lighting and white balance are adjusted.

Access pneumoperitoneum and port placement

Initial access is obtained by means of a Veress needle technique at the left anterior subcostal port site because this site is generally safe from visceral injury (Fig. 5). Carbon dioxide pneumoperitoneum is established to a pressure of 15 mm Hg. A 5-mm VersaStep port (US Surgical Corporation), with the Veress-style needle within the dilating sheath, is inserted through the same skin incision after the pneumoperitoneum has been established. We prefer to use two insufflators to offset potential air leaks. The tapered-tip dilator is advanced through the




FIG. 2. Key Instrumentation for laparoscopic gastric bypass.

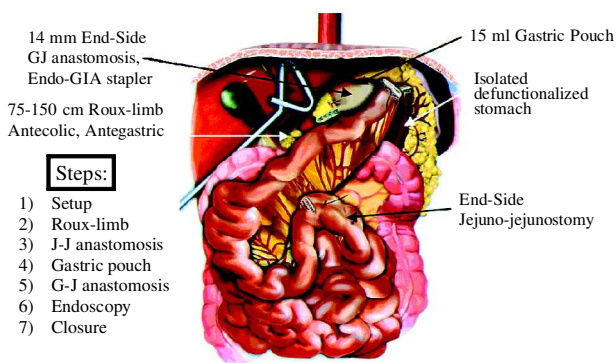


FIG. 3. Overview of laparoscopic gastric bypass: Univeristy of Pittsburgh approach.

sheath to avoid direct cutting of muscle. The remaining 5- to 12-mm VersaStep ports are inserted similarly under direct vision by means of the 5-mm (45-degree) scope through the anterior left subcostal port (Fig. 6). A 10-mm (45-degree) scope is placed in the left paramedian (12-mm) port. A liver retractor is placed through the posterior right subcostal port. The surgeon (standing on the right side) operates through the right upper abdominal port and right anterior subcostal port. The assistant surgeon (standing on the left side) operates through the two left subcostal ports. With two ports available, the assistant surgeon is much better able to operate. Usually, the assistant surgeon holds a grasping instrument in one hand and a suction device in the other to maintain a clean field. Figure 7 shows the complete operating room setup. The AESOP robotic camera holder and the Hermes voice activation system are used to enhance surgeon control and efficiency. A steep reverse Trendelenburg position exploits gravity to facilitate exposure of the stomach during creation of the gastric pouch and gastrojejunal anastomosis.

Initial inspection and construction of the Roux-limb

After positioning and port placement have been completed, the abdomen is inspected and adhesions are lysed with blunt and sharp dissection as needed. With the patient in the supine position, the omentum is advanced toward the upper abdomen to expose the ligament of Treitz. The jejunum is measured 50 cm from the ligament of Treitz; an intestinal grasper is used as a measuring device (it is marked 10 cm from the tip) (Fig. 8). The jejunum is positioned in a C configuration to facilitate placement of the Endo-GIA stapler for division. The Endo-GIA stapler is placed through the right upper abdominal 12-mm port and applied perpendicular to the jejunum and parallel to the mesenteric vascular arcade to

create the biliopancreatic limb and Roux-limb (Fig. 9A). The “white vascular” cartridge (2.5-mm staple height, 60-mm cartridge length) is used to minimize staple line bleeding. In this and all subsequent staple applications, six staggered rows of staples (three rows on each side) are used to reduce bleeding and staple line dehiscence. Two or three applications of the “gray cartridge” (2.0-mm staple height, 45-mm cartridge length) across the jejunal mesentery provide sufficient length for the Roux-limb to reach over the colon (antecolic) to the gastric pouch (Fig. 9B). Care is taken to avoid devascularizing the divided jejunal ends by applying the stapler at a point equidistant from the mesenteric border of each limb. With use of the EndoStitch suturing device (US Surgical Corporation), a 5-cm, 1/4-in Penrose drain is sutured to the Roux-limb end with 2-0 braided polyester (Surgidac; US Surgical Corporation) and used subsequently as a handle to advance the Roux-limb toward the gastric pouch to create the gastrojejunostomy (Fig. 9C). The Roux-limb is measured 75 cm distally (for patients with a body mass index < 50) or 150 cm distally (for those with a body mass index ≥ 50) (Fig. 10).

Jejunoo-jejuno-stomy

An end-side jejunoo-jejuno-stomy is shown in Figure 11. The Roux-limb is approximated to the biliopancreatic limb (1 cm from the end) at the antimesenteric borders with 2-0 Surgidac (Fig. 11A). The stitch is used as a stay suture during creation of the anastomosis (Fig. 11B). By means of ultrasonic dissection (Ultrasears; US Surgical Corporation), enterotomies are made at the biliopancreatic corner and antimesenteric border of the Roux-limb (Fig. 12 A-C). The enterotomy of the Roux-limb is made

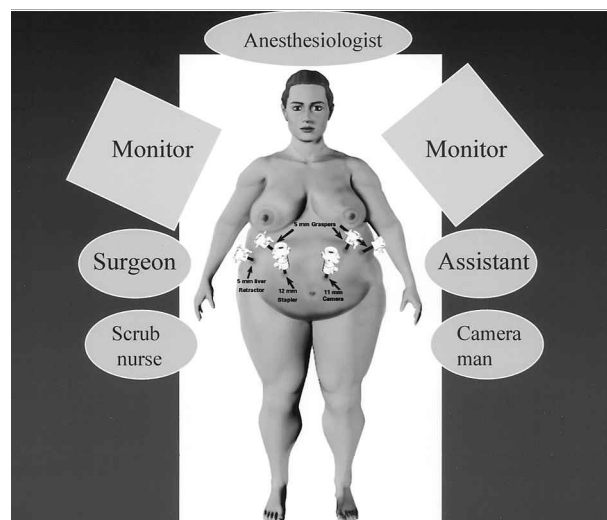


FIG. 4. Setup for laparoscopic gastric bypass.

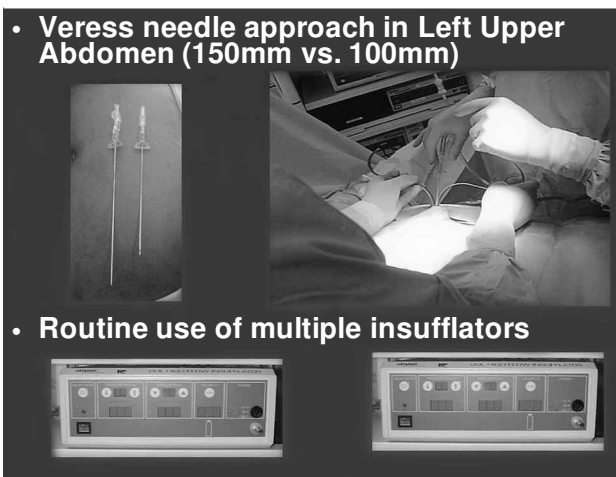


FIG. 5. Veress needle access.

1 cm proximal to the biliopancreatic enterotomy to facilitate stapler insertion (Fig. 12D). The Endo-GIA stapler with the 60-mm white load is inserted through each enterotomy and applied to create the end-side anastomosis (Fig. 13 A–D). Sutures (2-0 Surgidac) are placed to reinforce the crotch of the anastomosis and approximate the enterotomy for closure (Fig. 13D). The enterotomy is secured by three-point fixation (corners grasped by instruments, middle secured by suture and lined up parallel to the stapler) (Fig. 14A). The Endo-GIA stapler with a 60-mm white load is applied across the enterotomy (Fig. 14B). Care is taken to ensure that the lumen on the Roux-limb side is not compromised (Fig. 14C). An anti-obstruction stitch (Brolin stitch) is applied to approximate

the Roux-limb to the biliopancreatic limb proximal to the anastomosis (Fig. 15 A,B). This is intended to prevent the afferent limb from folding back on itself and causing an obstruction. The jejunio-jejunostomy is completed by closing the mesenteric defect with a running suture (2-0 Surgidac) (Fig. 16 A,B). An internal hernia resulting in a bowel obstruction may develop if the defect is left unclosed. We recommend a permanent suture to minimize reopening of the defect.

Advancement of the Roux-limb

The omentum is divided by mean of ultrasonic dissection from the transverse mesocolon to its inferior edge (Fig. 17 A,B). Dividing the omentum reduces tension on the Roux-limb as it passes in front of the colon up to the gastric pouch. Careful attention is paid to ensure that the Roux-limb mesentery is not twisted and its vascular supply compromised.

Creation of the gastric pouch

The patient is transferred to a steep reverse Trendelenburg position to facilitate exposure of the upper abdomen. The upper stomach is exposed by retracting the liver anteriorly with a 5-mm flexible retractor (Snowden Pencer) (Fig. 18A). By means of ultrasonic dissection, a window is created in the “bare area” of the gastrohepatic ligament immediately anterior to the caudate lobe of the liver. The opening in the gastrohepatic ligament provides quick and direct access to the lesser sac behind the stomach (Fig. 18B). After it has been ascertained that the orogastric tube has been withdrawn, the Endo-GIA stapler with a 60-mm white load is used to divide the lesser

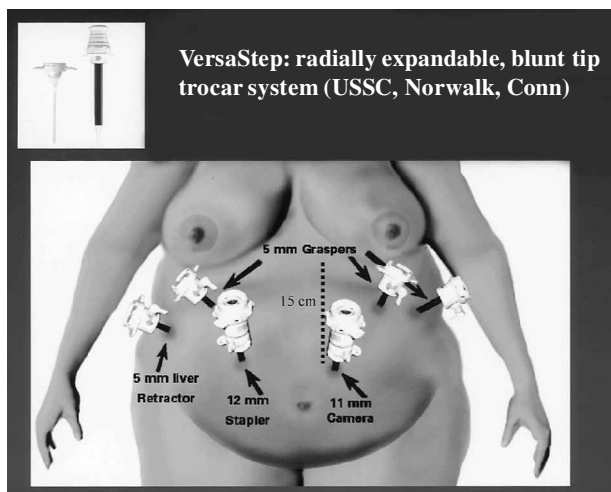


FIG. 6. Trocar placement.

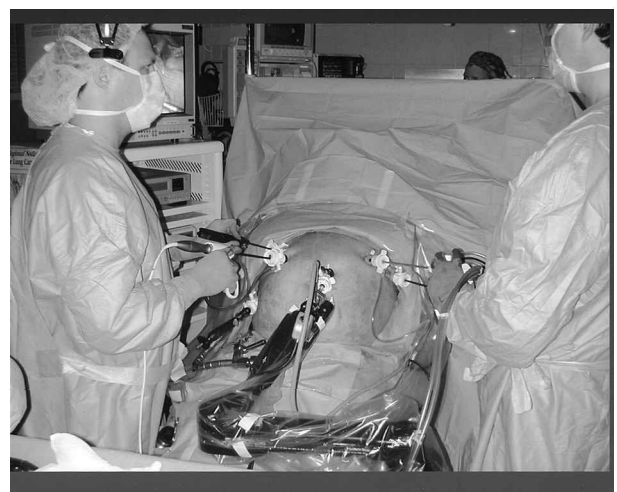

FIG. 7. Operating room setup.

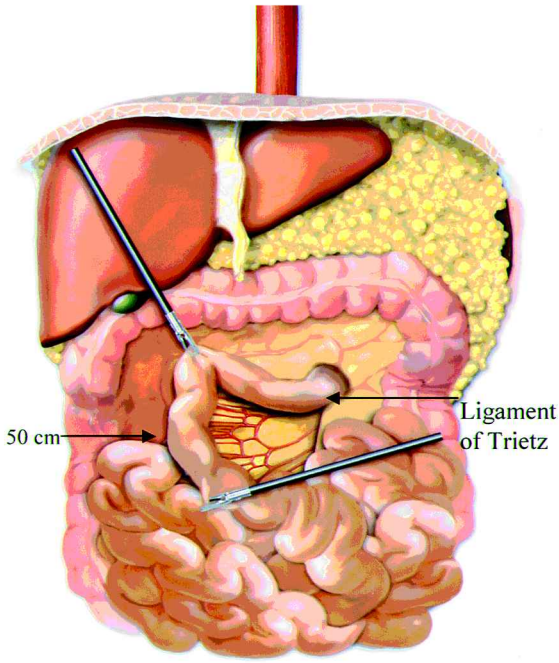


FIG. 8. Roux-limb creation.

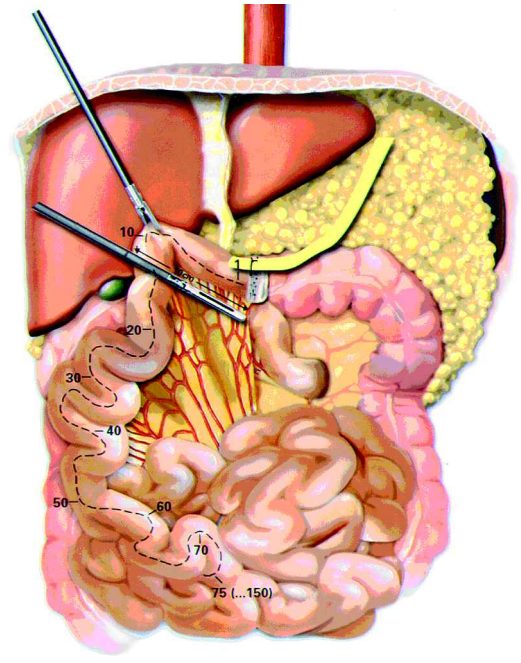


FIG. 10. Measurement of roux-limb.

omentum 1 cm distal to the gastroesophageal junction (demarcated by the epigastric fat pad) (Fig. 19A). The tip of the stapler overlaps the lesser curve by 1 cm. Dividing the lesser omentum does transect the nerve of Latarjet, but this has not resulted in any short- or long-term adverse affects in more than 1000 cases. The Endo-GIA stapler with 60-mm blue loads is then applied two to three times across the gastric cardia (1 cm from the gastroesophageal junction) toward the angle of His to create a gastric pouch of approximately 15 mL (Fig. 19 B-E). A reticulating staple cartridge (US Surgical Corporation) is sometimes helpful here, especially when it is difficult to reach the angle of His. The staple lines on both sides of

the transected stomach are examined to ensure that they are intact and not bleeding (Fig. 19F). The Roux-limb is then advanced toward the gastric pouch in preparation for the first layer of the end-side gastrojejunal anastomosis.

Creation of the gastrojejunostomy

The antimesenteric border of the Roux-limb is approximated to the posterior wall of the gastric pouch with running 2-0 Surgidac sutures (Fig. 20 A,B). A gastrostomy and then an enterotomy are made by means of ultrasonic dissection to provide access for the stapler (Fig. 20 C,D). The Endo-GIA stapler with a 45-mm blue load is inserted 1.5 cm into the gastric and jejunal lumina and then applied to create the end-side gastrojejunal anastomosis (Fig. 20 E,F). The resultant enterotomy is closed with absorbable suture (2-0 Polysorb; US Surgical Corporation). Sutures are placed at each corner, then tied in the middle after the 30F flexible endoscope has been inserted and used as a stent (Fig. 21 A-C). The sutures are tied down tightly against the endoscope like a purse string to achieve a 30F lumen (12- to 14-mm diameter). A second layer of suture (2-0 Surgidac) is applied anteriorly to oversew the entire anastomosis and gastric pouch staple line, thus completing the two-layer anastomosis (Fig. 22 A,B). A clamp is placed distal to the endoscope, and insufflation with the endoscope is performed with the anastomosis submerged in saline solution to examine for occult air leaks. If a leak is present, it is oversewn with

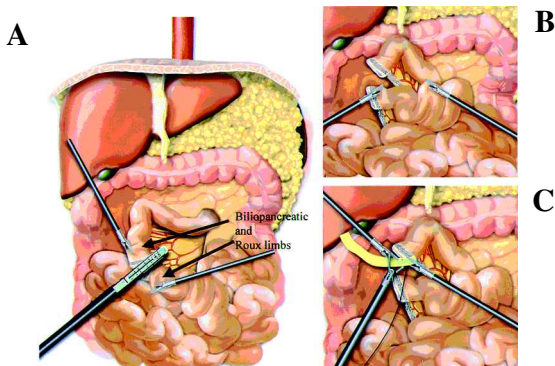


FIG. 9. Division of jejunum and mesentery.

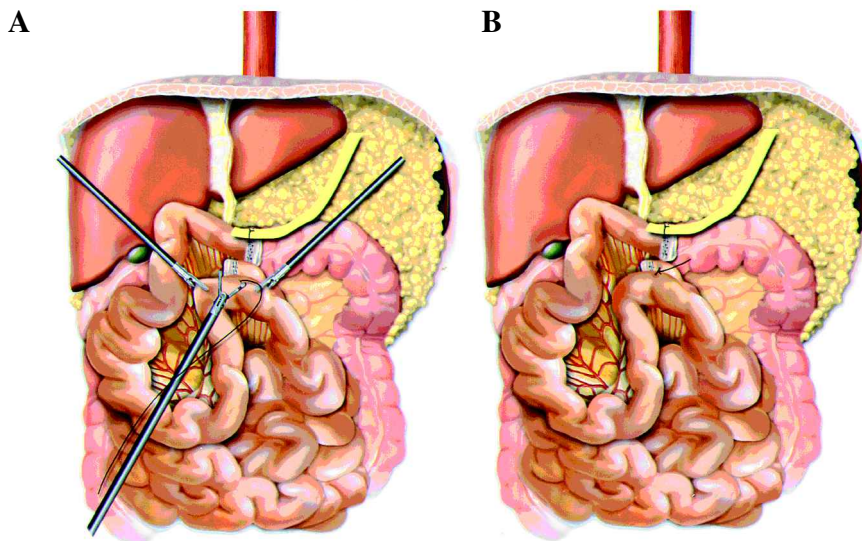


FIG. 11. Setup for end-side Jejunostomy.

2-0 Surgidac. The gastric pouch is then covered with an omental patch (“shower cap”) to protect against leakage, and a No. 15 round suction drain is placed posterior to the anastomosis. The drain is usually withdrawn on post-operative day 7. All port sites 10 mm and larger are closed with fascia stitches of 0 Polysorb. All carbon dioxide is evacuated, and the skin incisions are closed with interrupted 4-0 Polysorb.

OUTCOMES

The results of our first 275 patients with up to 2.5 years of follow-up were published in 2000.⁵ In most of the operations in this series, the circular stapler technique was used for the gastrojejunostomy, and all the patients received a retrocolic, retrogastric Roux-limb. The conver-

sion rate to open gastric bypass was 1%. An oral diet was begun at a mean of 1.58 days after surgery, with a median hospital stay of 2 days and return to work at 21 days. The incidence of early major complications was 3.3%, and for minor complications, it was 27%. One death occurred, related to a pulmonary embolus (0.4%). The hernia rate was 0.7%, and wound infections requiring outpatient drainage only were uncommon (5%). Excess weight loss was 83% at 24 months and 77% at 30 months. In patients with more than 1 year of follow-up, most of the comorbid conditions had abated or resolved, and 95% reported a significant improvement in quality of life. Our current experience involves approximately 2000 patients with up to nearly 6 years of follow-up. Most of them underwent the gastrojejunostomy with linear stapler technique and received an antecolic, antegastric Roux-limb. Mean excess weight loss appears to be maintained at 65% to 70% at 5 years (unpublished data). Our experience suggests that laparoscopic Roux-en-Y gastric bypass effectively achieves sustained weight loss, relieves comorbid conditions, improves quality of life, and reduces recovery time and perioperative complications.

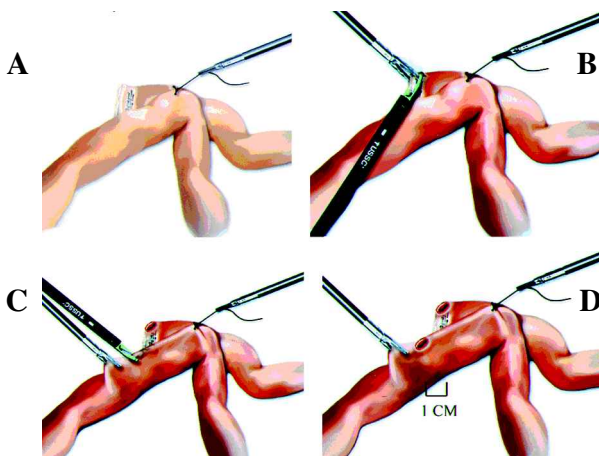


FIG. 12. Enterotomies for the Jeuno-Jejunostomy.

THE LEARNING CURVE

The laparoscopic gastric bypass is associated with a significant learning curve, perhaps more than many other advanced laparoscopic procedures. In our experience, the complication rates and operating times approached the levels reported for open gastric bypass after an experience of 100 cases.⁹ The acquisition of advanced laparoscopic skills is essential for the safe and effective performance of laparoscopic gastric bypass. Surgeons

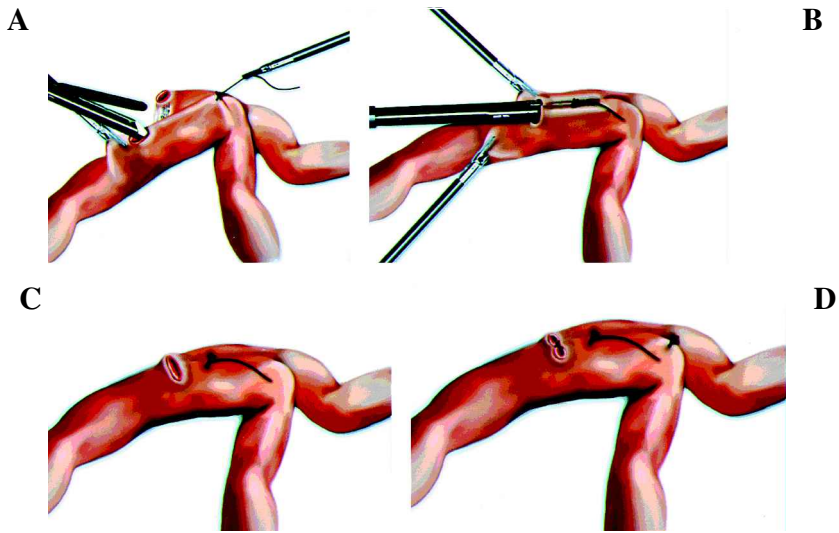


FIG. 13. Staple application for Jojuno-Jojunostomy.

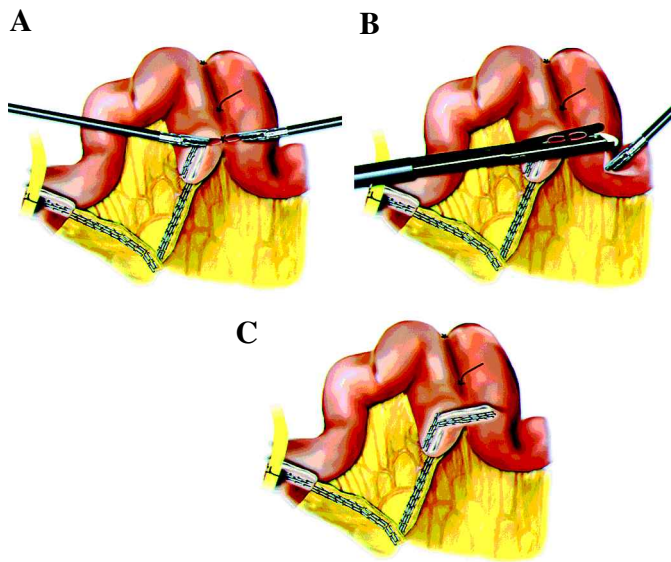


FIG. 14. Stapled closure of enterotomy.

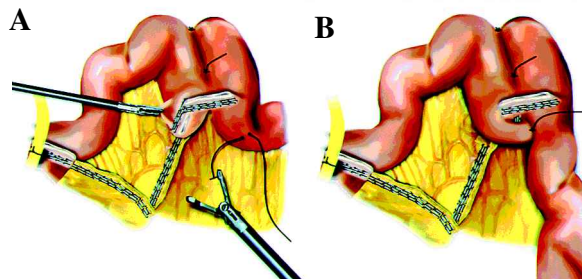


FIG. 15. Anti-obstruction stitch.

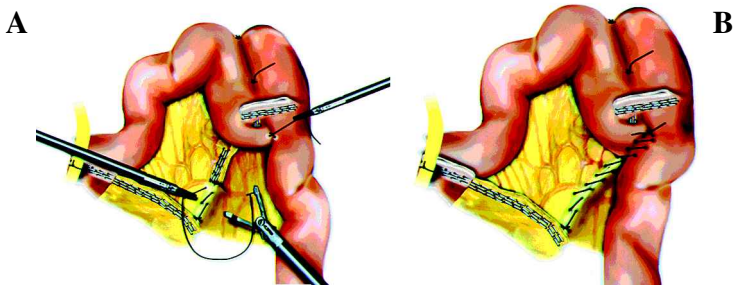


FIG. 16. Closure of mesentery.

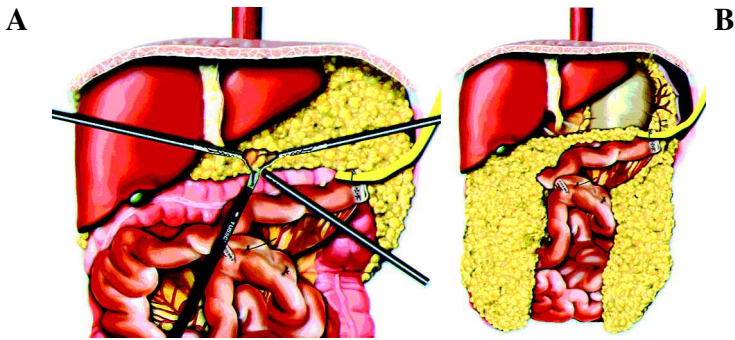


FIG. 17. Division of omentum.

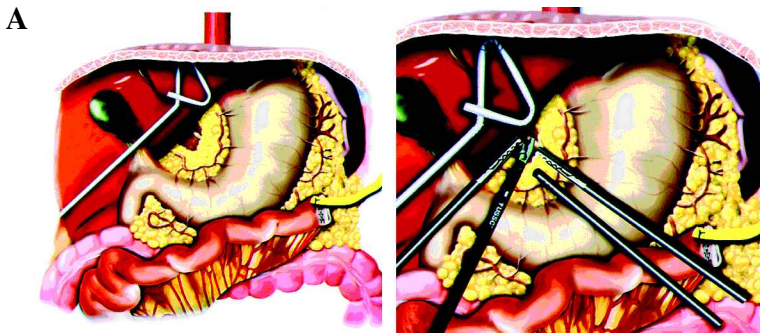


FIG. 18. Exposure of stomach and access to retrogastric space.

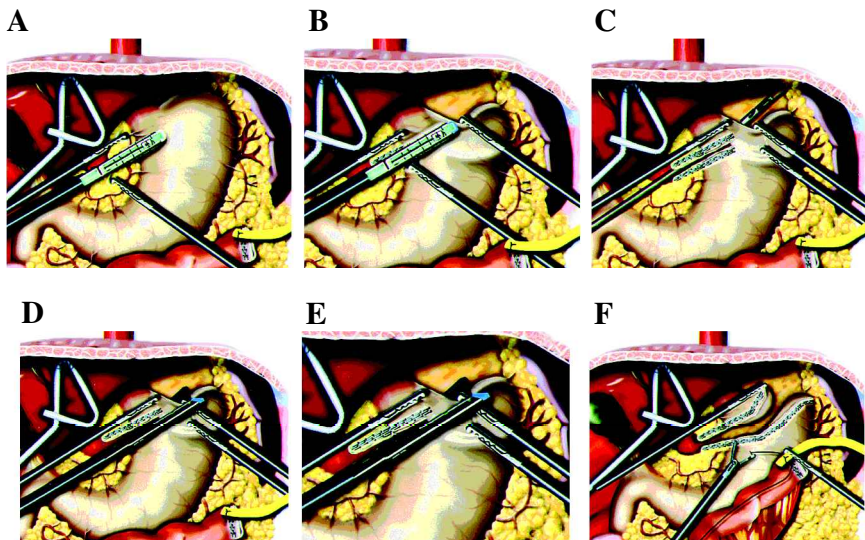


FIG. 19. Gastric pouch creation.

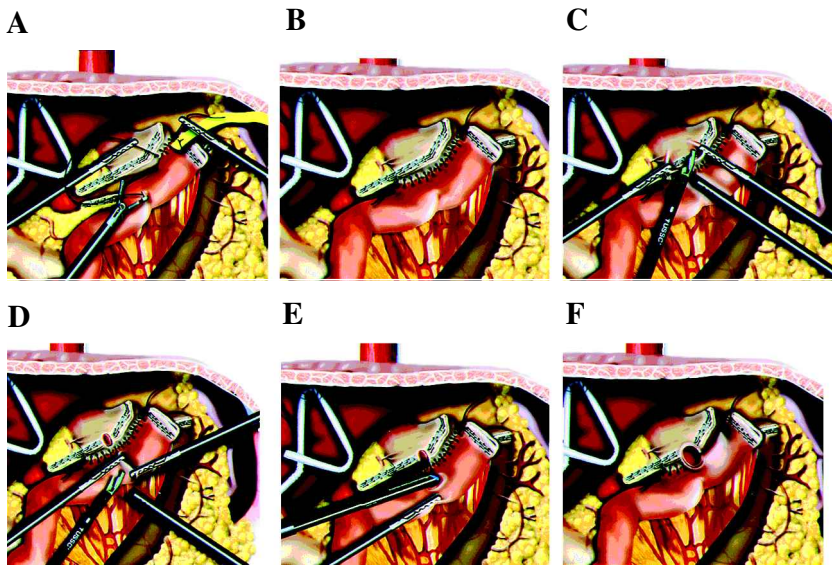


FIG. 20. Gastro-Jejunostomy.

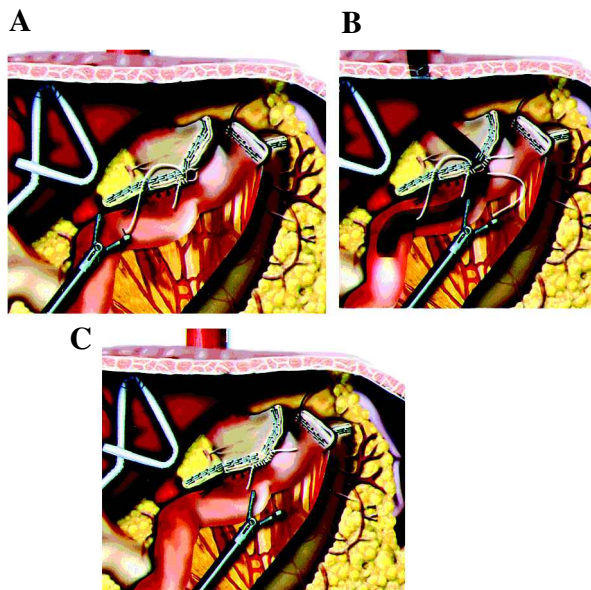


FIG. 21. Completion of Gastro-Jejunostomy.

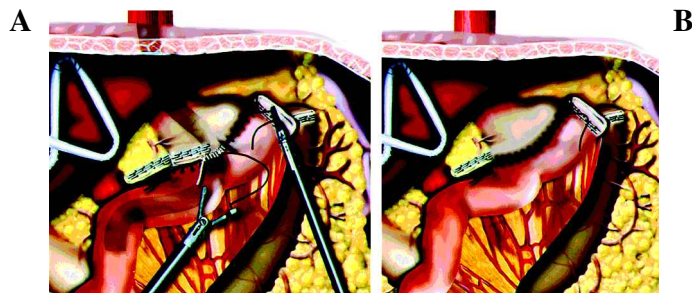


FIG. 22. Second layer closure.

without experience in at least some of the other advanced laparoscopic procedures will be at a significant disadvantage. Furthermore, surgeons not experienced in the perioperative management of bariatric patients may be equally vulnerable. For surgeons entering laparoscopic bariatric surgery, either fellowship training or extended mentoring by an experienced surgeon may be the optimal strategy to reduce patient morbidity related to the learning curve.

REFERENCES

1. Wittgrove AC, Clark GW. Laparoscopic gastric bypass: A five-year prospective study of 500 patients followed from 3 to 60 months. *Obes Surg* 1999;9:123-143.
2. Higa KD, Boone KB, et al. Laparoscopic Roux-en-Y gastric bypass for morbid obesity: Technique and preliminary results of our first 400 patients. *Arch Surg* 2000;135:1029-1033.
3. Champion JK, Hunt T, DeLisle N. Laparoscopic vertical banded gastroplasty and Roux-en-Y gastric bypass in morbid obesity. *Obes Surg* 1999;9:123.
4. Gagner M, Garcia-Ruiz A, Arca MJ, Heniford TB. Laparoscopic isolated gastric bypass for morbid obesity. *Surg Endosc* 1999;13:S6.
5. Schauer PR, Ikramuddin S, et al. Outcomes after laparoscopic Roux-en-Y gastric bypass for morbid obesity. *Ann Surg* 2000;232:515-529.
6. Schauer PR, Ikramuddin S. Laparoscopic surgery for morbid obesity. *Surg Clin North Am* 2001;81:1145-1179.
7. Nguyen, NT, Goldman C, Rosenquist CJ, et al. Laparoscopic versus open gastric bypass: A randomized study of outcomes, quality of life, and costs. *Ann Surg* 2001;234:279-289.
8. DeMaria EJ, Sugeran HJ, Kellum JM, et al. Results of 281 consecutive total laparoscopic Roux-en-Y gastric bypasses to treat morbid obesity. *Ann Surg* 2002;235:640-647.
9. Schauer PR, Ikramuddin SI, Hamad G, Gourash W. The learning curve for laparoscopic Roux-en-Y gastric bypass is 100 cases. *Surg Endosc* 2003;17:212-215.

Address reprint requests to:
Philip R. Schauer, MD
Magee Women's Hospital
Suite 5500
300 Halket Street
Pittsburgh, PA 15213-2582

E-mail: schauerpr@msx.upmc.edu