



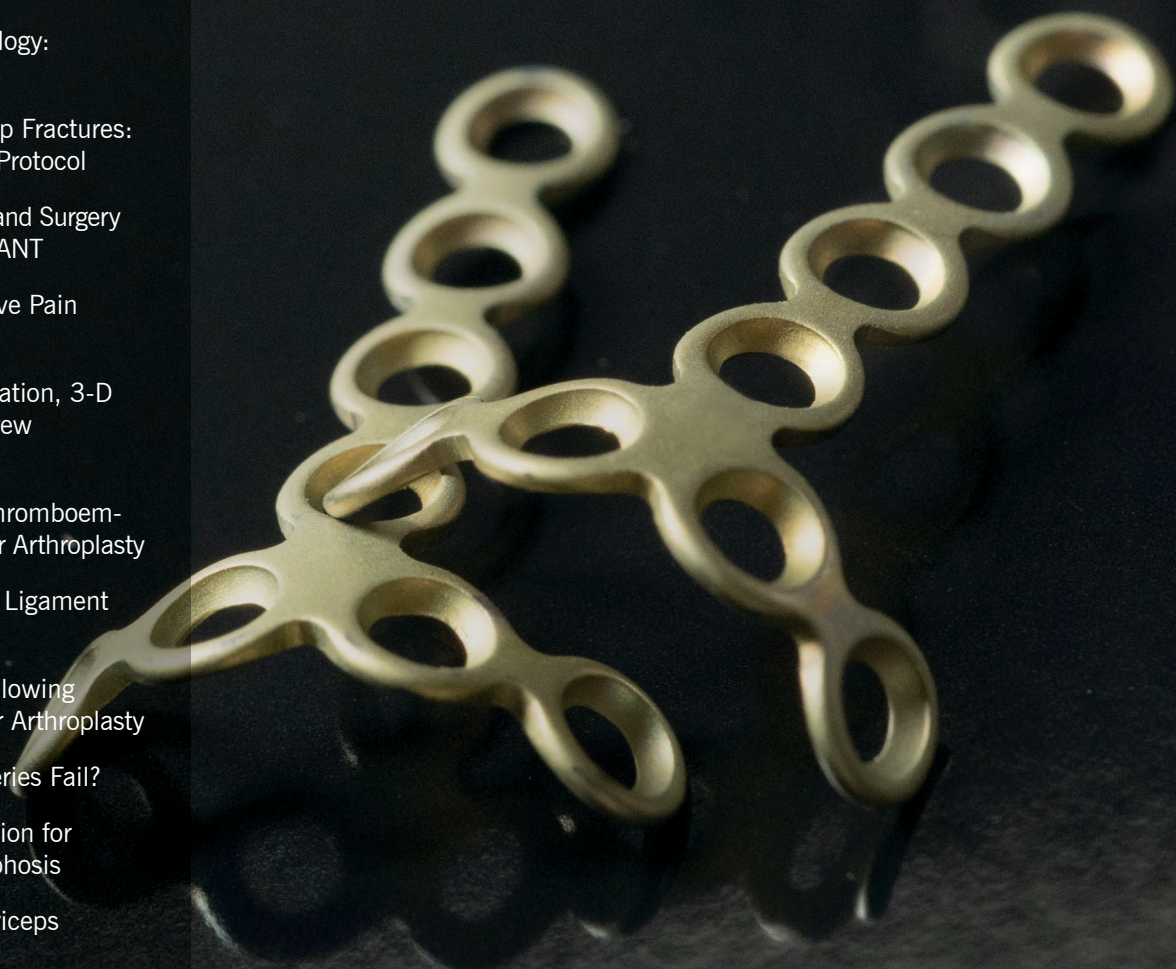
# ORTHOPAEDIC INSIGHTS

WINTER 2018

A PHYSICIAN NEWSLETTER FROM  
THE DEPARTMENT OF ORTHOPAEDIC SURGERY

## IN THIS ISSUE

- 3** Musculoskeletal Oncology:  
A Case Study
- 5** Managing Geriatric Hip Fractures:  
Our Multidisciplinary Protocol
- 6** Patients Undergoing Hand Surgery  
May Benefit from WALANT
- 8** Managing Postoperative Pain  
Without Opioids
- 10** Patient-Specific Navigation, 3-D  
Printing in Pedicle Screw  
Placement
- 12** Aspirin and Venous Thromboem-  
bolism Prevention After Arthroplasty
- 14** Medial Patellofemoral Ligament  
Reconstruction
- 16** Scapular Notching Following  
Reverse Total Shoulder Arthroplasty
- 18** Why Do Bunion Surgeries Fail?
- 20** Vertebral Body Resection for  
Severe Congenital Kyphosis
- 22** Neuromuscular Quadriceps  
Stimulation and TKR
- 23** Residency Update 2017



# DEAR COLLEAGUES



This issue of *Orthopaedic Insights* features many examples of how our experts in various subspecialties are improving patient outcomes and decreasing costs by refining new diagnostic and treatment methods. This team's accomplishments are many.

Here are highlights:

- Continuing our exemplary patient care as our No. 1 priority.
- Maintaining our *U.S. News & World Report* ranking as the No. 3 orthopaedic surgery department in the country.
- Optimizing use of advanced practice providers, resulting in a significant increase in patient access.
- Developing virtual visit and rounding programs that improve patient access and patient satisfaction.
- Hiring over 20 new attending physicians.
- Development of a new center of excellence for Hand and Upper Extremity Surgery in collaboration with the Dermatology & Plastic Surgery Institute.

- Adding robotic technology to the Cleveland and Florida orthopaedic service line for joint replacement.
- Establishing a multidisciplinary Cleveland Clinic Joint Preservation Center.
- Advances in our research program that are supported by National Institutes of Health, Patient-Centered Outcomes Research Institute and multiple industry-funded grants.
- One of the most productive years for national and international presentations and publications.
- Newly appointed directors for the centers of:
  - Foot and Ankle, Mark Berkowitz, MD
  - Trauma, Damien Billow, MD
  - Tumor, Nathan Mesko, MD
  - Shoulder, Eric Ricchetti, MD
  - Hand and Upper Extremity, Steven Maschke, MD

I'd like to acknowledge and thank Michael A. Mont, MD, for his tenure as Chairman of the Department of Orthopaedic Surgery. We all wish him well in his new endeavors.

Thank you for perusing this issue of *Orthopaedic Insights*, and for collaborating with us in the coming year on patient care, research and educational endeavors.

*Joseph P. Iannotti*

JOSEPH P. IANNOTTI, MD, PHD

Acting Chairman, Department of Orthopaedic Surgery  
Chairman, Orthopaedic & Rheumatologic Institute

216.445.5151 | iannotj@ccf.org



*U.S. News & World Report*

Cleveland Clinic's orthopaedics program is ranked No. 3 in the nation in *U.S. News & World Report's* "Best Hospitals" survey — the top-ranked program in Ohio.

---

ORTHOPAEDIC INSIGHTS | WINTER 2018

*Orthopaedic Insights* is published by Cleveland Clinic's Department of Orthopaedic Surgery to inform musculoskeletal specialists about advances in diagnosis, medical and surgical management, and research.

**Joseph P. Iannotti, MD, PhD**

Chairman, Orthopaedic & Rheumatologic Institute

**Sandra Erlanger**, Managing Editor

**Barbara Ludwig Coleman**, Graphic Designer

**Stephen Travarca**, Cover and Page 7 Photography

**Beth Lukco**, Marketing Manager

*Orthopaedic Insights* is written for physicians and should be relied on for medical education purposes only. It does not provide a complete overview of the topics covered and should not replace a physician's independent judgment about the appropriateness or risks of a procedure for a given patient.

© 2018 The Cleveland Clinic Foundation

# MULTIDISCIPLINARY CARE IN MUSCULOSKELETAL ONCOLOGY: A CASE STUDY

## SARCOMA PROGRAM BRINGS TOGETHER SPECIALISTS, PROVING WE'RE BETTER TOGETHER

A young man in his early 20s presented to the Musculoskeletal Tumor Center with progressively worsening left hip pain. He had had a total hip replacement at another institution a year and a half prior to presentation for a pathologic femoral neck fracture (Figure 1). He had an uneventful recovery until July 2017, when walking became increasingly more painful. Radiographs demonstrated an aggressive destructive mass surrounding his femoral implant (Figure 2) and pulmonary metastases (Figure 3). The mass was biopsied and confirmed to be a recurrent benign giant cell tumor of bone (Figure 4). His hip mass was treated with wide resection and reconstruction with an allograft-prosthetic composite (Figure 5).

### Collaboration: Vital to successful management

The successful care of this patient involved at least five medical specialties: radiology to interpret his multiple complex imaging evaluations and perform image-guided biopsy, pathology to interpret biopsy results, medical oncology to discuss pulmonary findings and develop a treatment plan, orthopaedic surgery to carry out the operation, and physical therapy to safely guide rehabilitation.

Multidisciplinary collaboration is imperative to providing high-quality care to patients with a musculoskeletal tumor diagnosis — which can range from malignant sarcomas, metastatic cancer involving muscle or bone, to complex benign aggressive tumors, such as the one described here.

MULTIDISCIPLINARY COLLABORATION IS IMPERATIVE TO PROVIDING HIGH-QUALITY CARE TO PATIENTS WITH A MUSCULOSKELETAL TUMOR DIAGNOSIS.

### Sarcoma Program and tumor board

Our comprehensive multidisciplinary Sarcoma Program allows us to better serve our patients by streamlining care across multiple disciplines, enabling us to diagnose and treat patients with great efficiency.

The program includes orthopaedic surgeons, other surgical subspecialists, medical oncologists (adult and pediatric), radiation oncologists, pathologists, radiologists, palliative medicine specialists, psychosocial oncologists and other practitioners. Each discipline plays a vital role in the care of the sarcoma patient.

Our sarcoma tumor board, which meets weekly, facilitates optimal communication and patient care. All core disciplines are present and submit cases and contribute to the discussion. We discuss treatment options and come to a consensus at tumor board meetings, including one for the young man described above. In this case, the consensus was that in addition to treatment of the primary recurrent tumor location (hip) with wide resection, medical treatment with denosumab was recommended for pulmonary metastases.

### Care paths under development

An additional initiative involves developing specific care paths structured around certain bone and soft tissue sarcoma diagnoses. The care paths reflect our team's agreement about how best to evaluate patients, to structure timing of multidisciplinary treatments, and to determine frequency and type of disease surveillance patients should receive. Care paths help reduce unnecessary tests and time to treatment as well as streamline processes in a way that is beneficial to patients and clinicians.

The treatment of sarcoma requires a tremendous amount of very specialized expertise and care coordination. The only way to combat sarcoma and similar diseases is through collaboration across all medical specialties. At Cleveland Clinic, we are committed to doing just that.

*Dr. Nystrom, who joined the Department of Orthopaedic Surgery in 2017, specializes in orthopaedic oncology. Dr. Mesko is Director of the Musculoskeletal Tumor Center.*



Lukas Nystrom, MD  
nystrol@ccf.org  
216.445.7164



Nathan Mesko, MD  
meskon@ccf.org  
216.444.4603

See figures, page 4.

Figure 1  
Preoperative CT (left) demonstrating pathologic fracture through a radiolucent lesion in the left femoral head/neck extending to the level of the lesser trochanter; and postoperative radiograph (right) demonstrating reconstruction with a total hip arthroplasty.

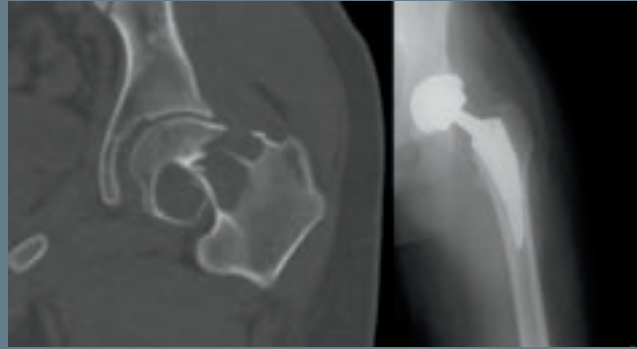


Figure 2  
Left hip radiograph at the time of presentation demonstrating a large destructive mass arising from the left proximal femur.

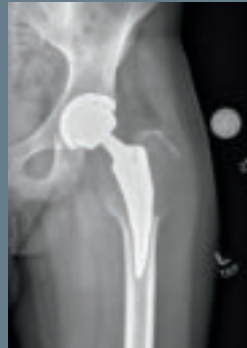

Figure 3  
CT scan of the chest demonstrating one of multiple pulmonary nodules suggestive of metastases.

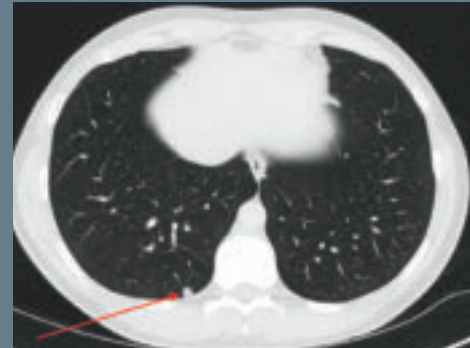


Figure 4  
CT-guided core needle biopsy (left) of the mass performed by our musculoskeletal radiologist; tissue obtained from the biopsy was confirmed as giant cell tumor of bone (right).

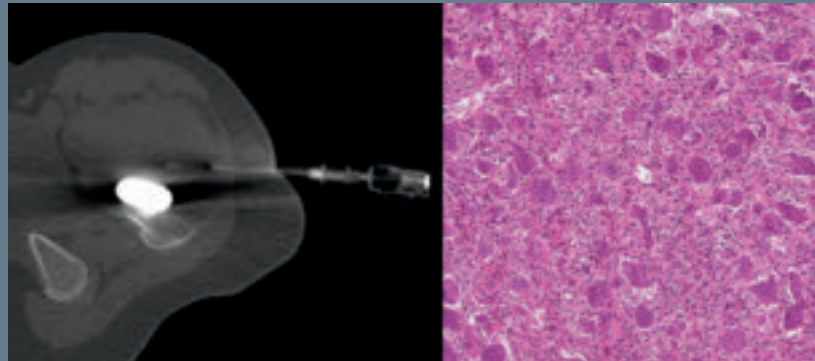
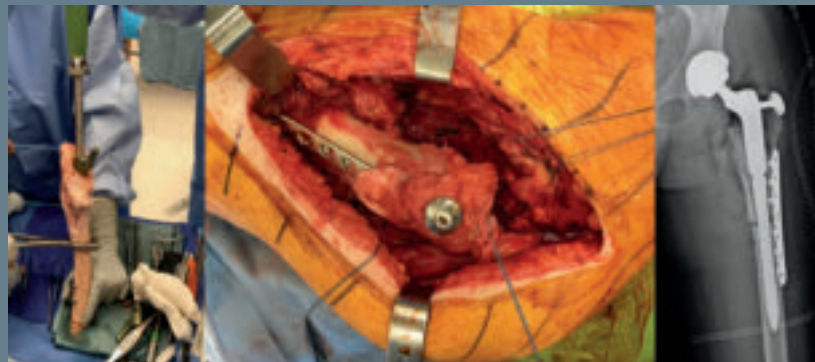

Figure 5  
The allograft being prepared on the back table (left); the allograft-prosthetic composite implanted in the patient with supplementary bolt fixation and plate to resist rotation (center); postoperative radiograph (right) demonstrating reconstruction.



# COMANAGEMENT OF GERIATRIC HIP FRACTURES USING A DETAILED MULTIDISCIPLINARY PROTOCOL

## IMPROVING OUTCOMES AND SIMULTANEOUSLY DECREASING COSTS

Hip fractures are a common orthopaedic problem that is becoming more prevalent as our country's population continues to age. They most commonly occur in elderly patients and are associated with a high morbidity and mortality. In addition to the important effect they have on the patient, they also come at a major price to both hospital systems and society. Complications, mortality and costs are known to be less when surgery is performed in less than 48 hours.

Using a multidisciplinary team approach, we developed a protocol for the preoperative evaluation and optimization of elderly hip fracture patients to increase the percentage of patients getting to the OR in less than 48 hours. By doing so, we improved outcomes and decreased hospital costs.

Patients 65 years or older with a hip fracture were enrolled in our protocol. Patients with prior surgery to the affected hip or pathologic fractures and those who refused surgery were excluded. All patients received a standard laboratory and radiographic workup. Chest X-rays, deep vein thrombosis duplex ultrasounds, and internal medicine and anesthesia consults were obtained based on agreed-upon indications. Other consults, such as cardiology and pulmonary, were obtained at the discretion of internal medicine staff. Time frames were established for evaluation by consultant services. A customized history and physical note and order set were created and embedded in our electronic medical record (EMR).

Patients were enrolled in our protocol from Aug. 1, 2016, through March 30, 2017, and compared with a similar population from the preceding 10 months. Outcome measures were collected from our EMR and included time to surgery, hospital length of stay, patients to surgery < 48 hours, in-hospital mortality, 30-day mortality and readmission, 90-day mortality and readmission, intensive care unit (ICU) admission and length of stay, in-hospital complications, and time to consult.

Twenty-six patients were consecutively enrolled in our pilot cohort and compared with 43 patients in the pre-pilot cohort. The two groups were similar in regard to Charlson Comorbidity Index, age, ASA class and treatment by 13 various surgeons.

For those patients requiring an internal medicine consult, there was a significant decrease in time to evaluation in the pilot group. Consult time was shortened from 8.8 hours to 3.5 hours ( $P < 0.001$ ). Consult time was also decreased by 8.4 hours in patients requiring cardiology evaluation for preoperative optimization ( $P = 0.011$ ).

### Median hours to surgery decrease

Secondary to this, median hours to surgery decreased from 34.0 to 23.0 ( $P = 0.077$ ) and the percentage of patients who went to surgery in less than 48 hours increased from 67.4 percent to 88.5 percent ( $P = 0.082$ ).

Length of stay decreased by 1.2 days after implementation of the protocol ( $P < 0.23$ ).

Of the 43 pre-pilot patients, 16 (37.2 percent) required postsurgical ICU admission. Pilot cohort postsurgery ICU admission rates were significantly lower at 11 percent ( $P < 0.05$ ).

In-hospital mortality decreased from 9.3 percent in the pre-pilot cohort to 0 percent in the pilot group ( $P = 0.29$ ). At 30 days, mortality decreased by 7.8 percentage points in the pilot group ( $P = 0.40$ ), from 11.6 percent to 3.8 percent. Ninety-day mortality rates were significantly lower in the pilot cohort compared with the pre-pilot cohort (3.9 percent and 27.9 percent, respectively,  $P < 0.05$ ).

Hospital readmission was also assessed at 30 and 90 days postoperatively and was down in all groups. Postoperative complications, including pressure ulcers, pneumonia, pulmonary emboli and deep venous thrombi all decreased.

### Average direct costs decreased as well


The average direct cost to the hospital per hip fracture patient decreased 26.1 percent between the pre-pilot and pilot groups after implementation of the protocol.

By developing and implementing a multidisciplinary protocol for preoperative evaluation and optimization of elderly hip fracture patients, we were able to get patients seen earlier by consultant services and operated on sooner. This led to decreased ICU admissions, lengths of stay, in-hospital 30- and 90-day mortality rates, 30- and 90-day readmission rates, and average direct costs to the hospital. Cooperation from physicians across multiple disciplines made this possible.

*Dr. Billow is Section Head of Orthopaedic Trauma. Dr. Worrell is a resident, Dr. Okrent is in the Continuous Improvement Department and Dr. Cereijo is a fellow at Vanderbilt University Medical Center. Dr. Whinney is a hospitalist.*



**Damien G. Billow, MD**  
billowd@ccf.org  
216.445.4570



**Cesar M. Cereijo, DO**



**Daniel Worrell, DO**  
worreld@ccf.org



**Michael Okrent, ScD**  
okrentm@ccf.org  
216.346.0547



**Christopher Whinney, MD**  
whinnec@ccf.org  
216.444.0933

# PATIENTS UNDERGOING HAND SURGERY MAY BENEFIT FROM WIDE-AWAKE LOCAL ANESTHESIA WITH NO TOURNIQUET

## WALANT TECHNIQUE: A PATIENT-FOCUSED APPROACH



**William H. Seitz Jr., MD**  
216.363.2370  
seitzw@ccf.org



**Jacob P. Ehlers, MPAS, PA-C**  
ehlersj3@ccf.org  
216.363.2370

Cleveland Clinic is continually exploring ways to improve surgical techniques. One method being evaluated for hand and upper extremity operations is the wide-awake local anesthesia no tourniquet (WALANT) technique. WALANT uses only local anesthesia, without the need for a tourniquet. This approach may be used for procedures for a variety of diagnoses, including carpal tunnel syndrome, trigger finger, cyst removal and tenosynovitis/tendinitis. In some cases, WALANT may even be appropriate for tendon repairs.

Using WALANT is a very patient-focused approach and offers several advantages related to the type of anesthesia as well as the elimination of the tourniquet.

The risks of general or regional anesthesia, although few, are well-established. Some patients have comorbid conditions that are contraindications for general or regional anesthesia. Some patients who might not have been candidates for surgery based on their comorbidities could potentially be treated using WALANT. This type of surgery is generally reserved for unilateral procedures.

Wide-awake hand surgery can be performed without the need for preoperative testing or anesthesia consults. An intravenous catheter insertion is also unnecessary, and the requirement for monitoring during surgery is reduced. The procedure is performed in an aseptic operating room with minimal draping and instrumentation. This increases efficiency and markedly decreases waste of otherwise voluminous drapes and packaging.

### Increased convenience for patients

The use of local anesthesia eliminates the need for the usual overnight fasting, which means less inconvenience for patients. Patients with comorbid conditions, such as diabetes, do not need to alter their medication schedules.

In addition, local anesthesia means patients can stay focused and clear-headed, and they can be provided patient education

and instructions on postoperative care. Having patients fully engaged leads to improved understanding and outcomes.

### Improved surgical decision-making

Avoiding sedation may also allow patients to participate in a full range of active movements during the surgery. In some cases, observation of this movement can enable the surgeon to make adjustments during the procedure with the intention of improving clinical outcomes. For example, in performing surgery for a trigger finger, having the patient move actively can ensure complete release. When repairing a lacerated tendon, a surgeon can assess the adequacy of repair and smooth tendon gliding by asking the patient to actively move their finger.

New ways to inject local anesthesia with minimal pain have overcome another barrier to the use of local anesthesia. Furthermore, the type of local anesthesia used in WALANT provides good hemostasis, which allows the procedure to be conducted without the use of a tourniquet. Eliminating the tourniquet means reducing patient discomfort. In the past, enabling patients to tolerate the pressure

discomfort of the tourniquet was one of the reasons sedation had been needed for hand surgery.

With WALANT, pain and discomfort can be minimized and patients are able to rapidly return to daily function. Patients spend less time at the hospital with minimized recovery time, and most patients can simply get up and go home after the procedure. They do not need to have someone stay with them the evening of the surgery, which is often required after sedation.

WALANT surgery improves efficiency, patient safety and outcomes while minimizing discomfort and reducing drug use. It is a key addition to our commitment to improving the patient experience.

WITH WALANT, PAIN AND DISCOMFORT CAN BE MINIMIZED AND PATIENTS ARE ABLE TO RAPIDLY RETURN TO DAILY FUNCTION.

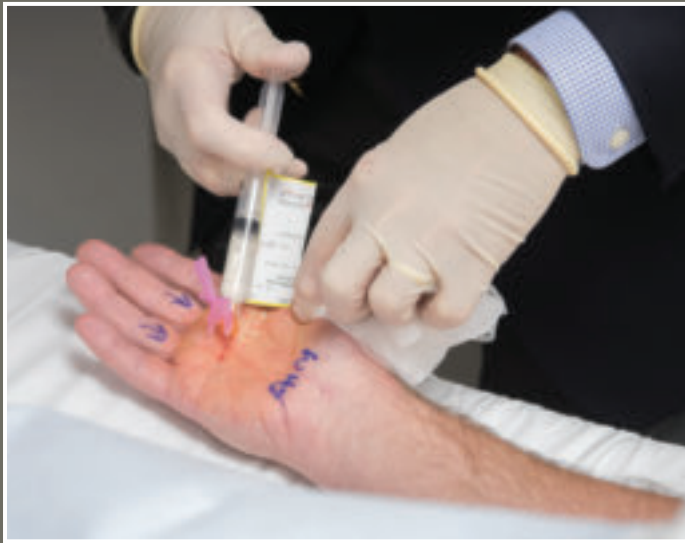

Figure 1

### WALANT Technique

Figure 1

Local anesthetic injection is performed under sterile conditions in the preoperative area. The combination of Xylocaine, epinephrine and bicarbonate offers complete anesthetic relief from pain while offering excellent hemostasis without the discomfort of a tourniquet. This affords excellent anesthesia, visibility and patient comfort.

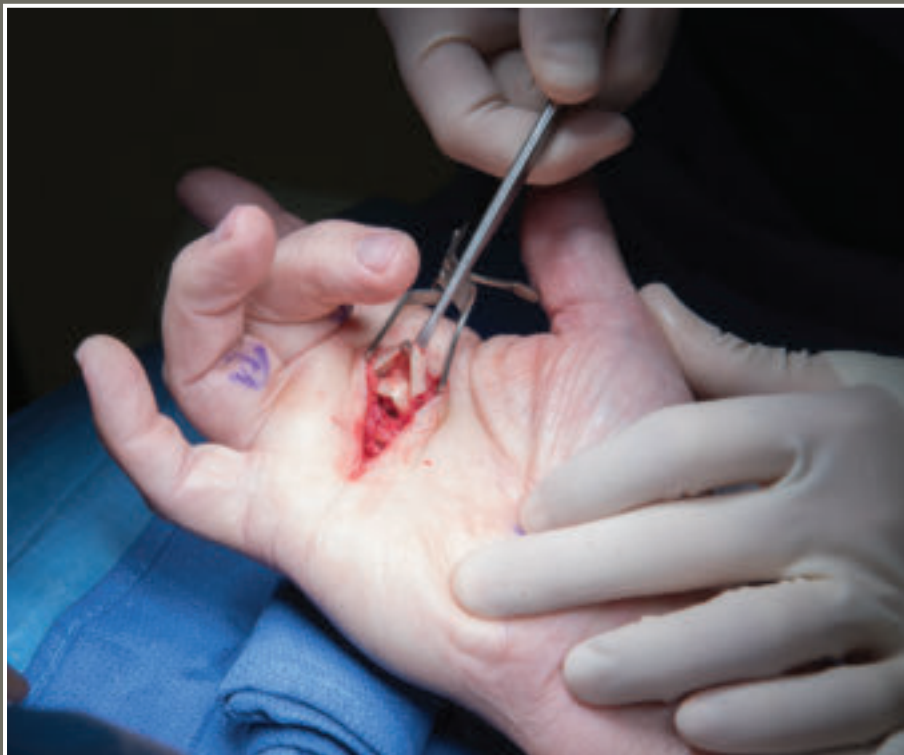

Figure 2

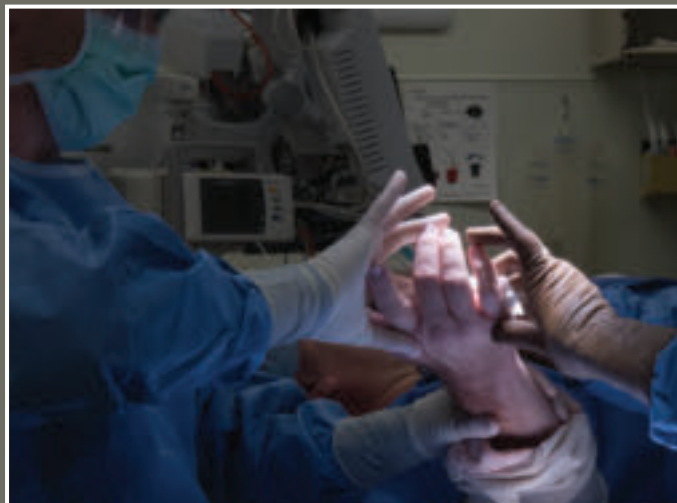Figure 2

Treatment for trigger finger of middle and ring fingers: Release has been performed and tendons surgically mobilized. Patient is able to demonstrate active finger movement without restriction or discomfort, demonstrating to the surgeon that surgery has been satisfactorily completed.

Figure 3

The WALANT procedure is performed in the operating room under sterile conditions and with minimal draping. Adequate hemostasis from preoperative injection eliminates the need for a tourniquet. This wide-awake approach allows intraoperative active range-of-motion testing of the repair prior to closure.

Figure 3



*Dr. Seitz is a hand and upper extremity surgeon and Chairman, Department of Orthopaedic Surgery, Cleveland Clinic Lutheran Hospital. Mr. Ehlers is a physician assistant.*

# MANAGING POSTOPERATIVE PAIN IN THE ORTHOPAEDIC PATIENT WITHOUT OPIOIDS

## WHAT IS THE ORTHOPAEDIC SURGEON'S ROLE IN PREVENTING ESCALATION OF A NATIONAL CRISIS?



**Vani J. Sabesan, MD**  
sabesav@ccf.org  
954.659.5430

Ninety Americans die of an opioid overdose daily, and while the United States represents only 5 percent of the global population, it is responsible for 80 percent of global opioid consumption and uses 99 percent of the global hydrocodone supply. Opioid abuse is a systemic and pervasive problem that presents a challenge for all medical specialties and especially orthopaedists, whose patients often require marked pain management postoperatively.

Orthopaedic surgeons are the third-highest prescribers of opioid-based medications. Recognizing our role and responsibilities in balancing pain management with helping patients avoid opioid dependency, a group of forward-thinking Cleveland Clinic Florida physicians is looking at ways to stem the tide.



**Danielle Malone, MPH**  
maloned4@ccf.org  
954.659.5430

### Multimodal pain management for shoulder surgery

Growth rates of total shoulder arthroplasty (TSA) are comparable to those of total hip and knee procedures in the U.S. As these numbers rise, postoperative pain management and optimization of outcomes are critical. Multimodal pain management is the current standard of care for TSA patients, incorporating anti-inflammatories, opioids, other analgesic medications and regional nerve blocks. One option for non-narcotic extended postoperative pain management is continuous interscalene nerve blocks (CISB). These have many advantages, but associated risks have led to exploration of alternatives, such as long-acting liposomal bupivacaine (LB). This agent has gained popularity for its potential to provide extended postoperative pain relief with fewer side effects.



**Kiran Chatha, MD**  
954.659.5430

We performed a prospective, randomized clinical trial to assess the efficacy of LB, and found significant reduction in opioid use at

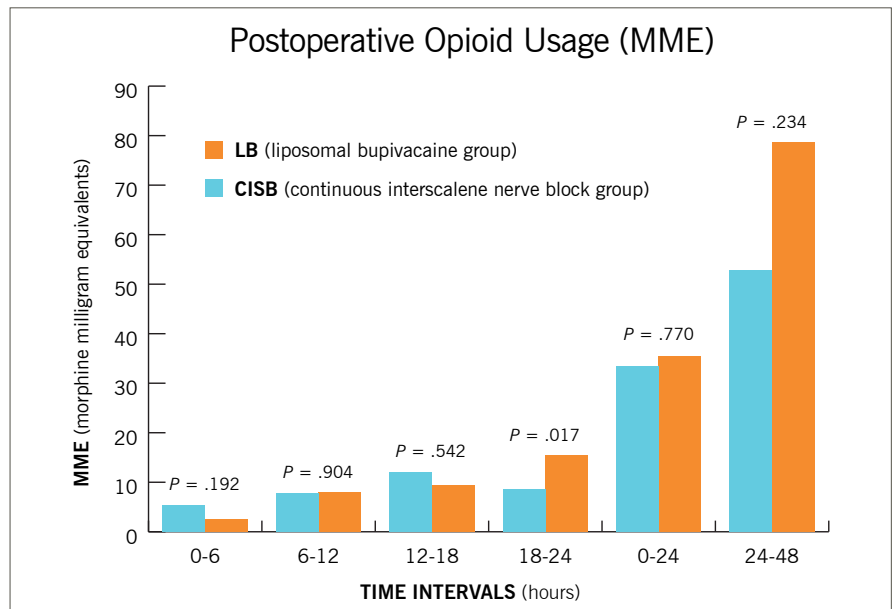
18-24 hours after surgery ( $P = 0.017$ ). The LB group had equivalent narcotic usage, pain scores and time to first narcotic rescue compared to the gold standard CISB group, but with fewer complications and cost, demonstrating that LB provides an excellent option for postoperative pain relief for shoulder arthroplasty patients (see chart below).

### Does preoperative opioid use affect outcomes?

To further delineate the effects of narcotic usage, we evaluated previous narcotic usage in a lower socioeconomic population undergoing rotator cuff repair. Preoperative opioid use has been correlated to suboptimal outcomes after orthopaedic surgeries. We found that opioid-dependent and opioid-naïve patients had significant improvements on all patient-reported and functional outcomes. However, the preoperative opioid-naïve patients demonstrated significantly better postoperative patient-reported outcome scores. Within the opioid cohort, Medicaid patients reported significantly lower subjective shoulder scores compared with non-Medicaid patients. Regardless of payer status, preoperative opioid use negatively impacted functional outcomes for all patients undergoing rotator cuff repairs.

### Chart

Postoperative opioid use in morphine milligram equivalents (MME). (Chart reprinted from the *Journal of Shoulder and Elbow Surgery* with permission from Elsevier. See reference.)





### Risk factors and registries

To better understand who develops postoperative opioid dependence, we developed a narcotic outcome database for TSA patients. We are examining over 2,000 patients who underwent shoulder surgery at Cleveland Clinic to understand how risk factors and diagnoses relate to postoperative dependence. Some clear trends have already emerged.

Orthopaedic patients are oftentimes already narcotic-dependent

upon initial presentation, and we may be overprescribing narcotics pre- and postoperatively. Our results also indicate that a majority of patients do not take all of the pills prescribed and report taking their narcotic medication only immediately postoperatively. We found a 3.5 times greater risk for postoperative dependence when TSA patients took narcotics for more than one month preoperatively. In the trauma population, we found that the management of upper extremity fractures with narcotics for extended periods of time prior to surgery may cause increased postoperative dependence and prolonged, higher doses of narcotics.

### Next phase: Patient education and empowerment

Inspired to decrease narcotic dependence in the orthopaedic population, we are seeking funding to launch a narcotic-free campaign that will begin with the creation of educational materials and development of a validated, narcotic-free postoperative pain management protocol that surgeons can use confidently.

ORTHOPAEDIC  
SURGEONS ARE THE  
THIRD-HIGHEST  
PRESCRIBERS OF  
OPIOID-BASED  
MEDICATIONS.

While creating a narcotic-free campaign in this population may seem a daunting task, we are confident that our unique protocol will facilitate success. Through educational tools and focus groups, patients will learn the implications of using opioids and that postsurgical pain can be managed effectively without narcotics.

We hypothesize that patients electing to forgo narcotics will have less dependence, equivalent functional outcomes and higher satisfaction levels compared with the narcotic group. If successful, our campaign will be extended to the much larger Cleveland Clinic total joint arthroplasty population.

Reversing the opioid crisis will take time, but orthopaedic surgeons at Cleveland Clinic Florida recognize that with the number of primary arthroplasties projected to jump to 3.5 million by 2030, now is the time to start.

*From the Levitz Department of Orthopaedic Surgery, Cleveland Clinic Florida, where Dr. Sabesan is an orthopaedic surgeon, Ms. Malone is a research coordinator and Dr. Chatha is a clinical research fellow.*

### References

Burkhart SS, Ricchetti ET, Levine WN, Galatz LM. Challenges and controversies in treating massive rotator cuff tears. *Instr Course Lect.* 2016;65:93-108.

Sabesan VJ, Shahriar R, Petersen-Fitts GR, Whaley JD, Bou-Akl T, Sweet M, Milia M. A prospective randomized controlled trial to identify the optimal postoperative pain management in shoulder arthroplasty: liposomal bupivacaine versus continuous interscalene catheter. *J Shoulder Elbow Surg.* 2017;26(10):1810-1817.

# PEDICLE SCREW PLACEMENT WITH PATIENT-SPECIFIC NAVIGATION, 3-D PREOPERATIVE PLANNING AND PRINTING

## IMPROVED ACCURACY AND FIXATION STRENGTH IN SPINE SURGERY



David Gurd, MD  
gurdd@ccf.org  
216.445.8001

Pedicle screws are indicated for placement in procedures ranging from two-level vertebral fusions to complex spine reconstructions (e.g., idiopathic scoliosis). There are multiple methods for placing pedicle screws, including a “freehand” method, wherein a surgeon targets the trajectory of the screw blindly and/or aided by intraoperative fluoroscopy based on experience or with the aid of complex intraoperative navigation tools that typically require a large amount of radiation. Despite current best efforts, complications still occur given the proximity of the spinal pedicles to major anatomic structures, including the spinal cord, esophagus, lungs and aorta.

### Can 3-D planning and printing improve outcomes?

As an alternative approach to this complex surgical procedure, we investigated whether outcomes could be improved with 3-D preoperative planning and patient-specific navigation (PSN) through use of a 3-D printed guide. Additionally, we sought to determine whether fixation strength of pedicle screw placement could be improved through a computer algorithm that targets an optimized pedicle screw trajectory. The study was presented at the 2017 Scoliosis Research Society annual meeting and course.

Through use of 3-D reconstruction software, five cadaver spines were virtually reconstructed and exported into a trajectory optimization software program for preoperative planning. One of two pedicles at each vertebral level from T1 to L5 was randomized to screw placement with either a PSN guide or through the freehand method, which served as a control. For the PSN-designated pedicles, an acceptable “start zone” was identified by a staff surgeon. Using a proprietary algorithm, each pedicle screw trajectory was optimized within the bounds of this start zone.

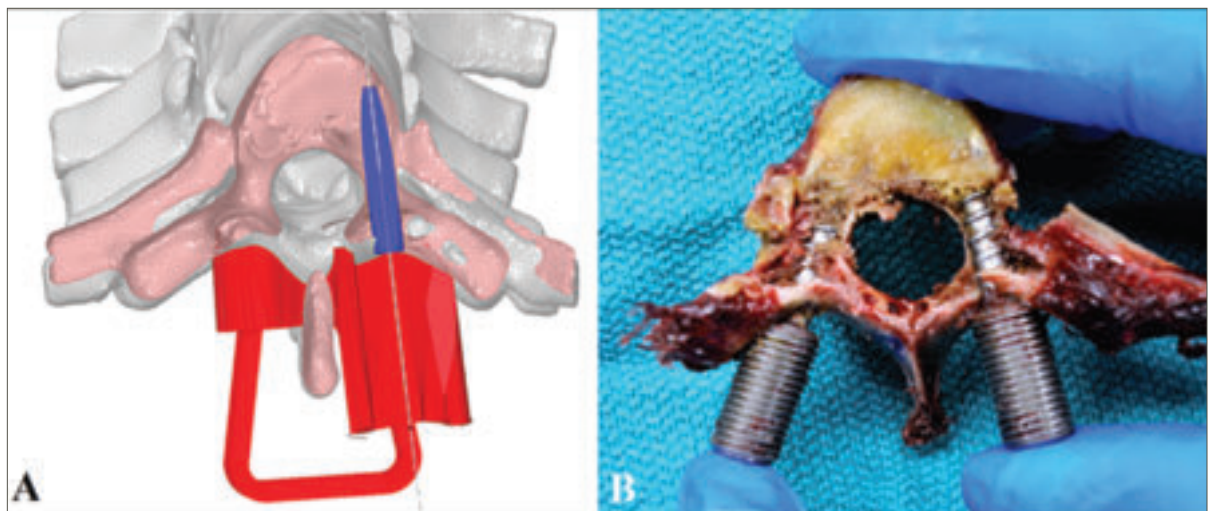
Once the ideal trajectory was identified, a PSN guide was virtually generated with a canal aligned to the planned trajectory. A portion of each guide was designed to interface with the posterior lamina at the individual vertebral levels. The guides were then 3-D printed using a high-resolution industrial printer with a material that can withstand high temperature and pressures, thus making it sterilizable for intraoperative use.

Figure 1 illustrates a virtual PSN guide aligned to the planned trajectory axis as well as the real-world screw that was placed with aid from the 3-D printed guide.

The five cadavers previously described were assigned to five different surgeons of varying experience, ranging from

Figure 1

(A) Axial slice of the virtually planned trajectory with the PSN device (red) and a surrogate screw (blue) aligned to the trajectory axis. (B) shows a similar axial cut in the real-world vertebrae with the PSN screen on the right and the freehand-placed screw on the left.



intern to senior staff. Each surgeon was tasked with placing a freehand pedicle screw and a PSN-guided pedicle screw at each level without the aid of intraoperative imaging. After a pedicle screw was placed at each level, the cadavers were rescanned by computed tomography (CT) and virtually reconstructed. The postoperative CT scans were then compared for accuracy with the preoperatively planned trajectory.

Across the five surgeons, accuracy of placement averaged less than 2.75 mm translation and 6.0 degrees angulation from the planned trajectory. Additionally, nearly half as many high-grade (grades 2 and 3) perforations were seen with the PSN-guided screws (13/84 versus 26/85).

In addition to an accurately placed screw, the average time to placement was over a minute faster for each screw placed using the PSN guide (136 +/- 80 seconds versus 201 +/-

82 seconds). This result is likely secondary to improved confidence during placement and less need for rechecking for pedicle perforation during each step of the process. The total operative room time, however, would likely be improved even further in a real-world setting as the use of intraoperative fluoroscopy and/or neuromonitoring would inform the surgeon if a screw was grossly misplaced and required adjustment.

ADVANCES IN 3-D RECONSTRUCTION AND PRINTING TECHNOLOGY HAVE GIVEN US THE ABILITY TO CREATE PSN GUIDES THAT CAN CONFORM TO COMPLEX BIOLOGICAL SHAPES.

Each vertebral level was dissected and harvested in a way that allowed axial load strength testing. Through use of the PSN guide and the optimization algorithm, the pedicle screws had, on average, 33.75 percent stronger fixation strength than the controls at each level. When looking at only the surgeons in this study who were post-residency, an average improvement in fixation strength of 28.6 percent was measured.

In this study, chosen screw size was controlled to avoid bias in either grouping, but the algorithm chose larger screws in over half of the PSN cases (31/59 biomechanically testable levels), which if used would have resulted in even stronger fixation at those levels.

#### Future directions

Advances in 3-D reconstruction and printing technology have given us the ability to create PSN guides that can conform to complex biological shapes. This technology can aid surgeons in rapid and accurate pedicle screw placement. Furthermore, coupling accurate placement with an optimization planning algorithm can improve fixation strength even for experienced surgeons. Moving forward, it will be important to test this in real-world scenarios to investigate the clinical implications of these technologies and their ability to improve operative time, radiation exposure to the patient and surgeon, and rates of hardware failure.

*Dr. Gurd is Head of Pediatric Spinal Deformity Surgery at Cleveland Clinic Children's. Kyle Walker, MD, former Cleveland Clinic orthopaedic surgery researcher, co-authored this article.*

# ASPIRIN DOSE AND VENOUS THROMBOEMBOLISM PREVENTION AFTER TOTAL HIP AND KNEE ARTHROPLASTY

REVIEW OF NEARLY 10,000 PATIENTS YIELDS DATA ON IDEAL EFFECTIVE DOSE FOR LOWEST RISK OF COMPLICATIONS



Carlos A. Higuera Rueda, MD  
higuerc@ccf.org  
216.636.1136



Mhamad Faour, MD  
faourm@ccf.org  
216.445.4909

Patients undergoing lower extremity total joint arthroplasty (TJA) are at risk of developing venous thromboembolism (VTE), which includes deep venous thrombosis (DVT) and pulmonary embolism (PE). Historically, the rate of DVT in patients undergoing TJA was between 35 and 85 percent without prophylaxis. Over time, surgical approaches and operative times improved dramatically: epidural and spinal anesthesia are often chosen preferentially, pneumatic compression pumps were introduced, and most important, patients are encouraged to mobilize earlier. Today, almost all physical therapy protocols recommend same-day, out-of-bed activities after surgery. With the introduction of these perioperative modifications, the incidence of VTE events underwent a dramatic reduction in clinically symptomatic DVTs and fatal PEs.

The incidence of VTE today is reported to be less than 1 to 2 percent. With such a low incidence and standardization of multimodal prophylaxis practices, however, it has become difficult to distinguish differences in efficacy between different chemoprophylactic modalities.

## Chemoprophylactic modalities abound, so is aspirin appropriate?

There is a wide and expanding array of VTE chemoprophylactic agents for patients undergoing TJA. Use of potent agents such as low-molecular-weight heparin, warfarin or newer anticoagulation agents has become the accepted practice. Many well-known challenges associated with these agents, including the risk of bleeding, wound-related infections, and difficulties with administration, titration and monitoring, were scrutinized in the search for an ideal chemoprophylactic agent.

Low-dose aspirin (81 mg) has been long-established as effective in preventing arterial thromboembolic events in cardiovascular and cerebrovascular diseases. The role of aspirin as an effective modality for the prevention of VTE following TJA has been described in the medical literature for many decades. Aspirin is well-tolerated, inexpensive and easy to administer, with no need for routine blood monitoring.

## Determining optimal dose

With the endorsement of aspirin in many published guidelines (American Academy of Orthopaedic Surgeons 2009 and 2011 and The American College of Clinical Pharmacy 2012) and additional emerging evidence demonstrating its efficacy, aspirin gained popularity in the orthopaedic community as an effective VTE prophylactic agent following TJA.

The only remaining question concerned optimal dose. If the current recommended regimen of 325 mg twice a day was efficacious, would a smaller dose (81 mg twice a day) be equally efficacious, given its pharmacodynamics, and also pose less risk of complications?

We retrospectively reviewed 16,000 medical records of primary TJA patients who were treated between 2012 and 2016. We identified 9,602 patients who received enteric-coated aspirin twice daily after surgery for four to six weeks. A total of 2,360 patients received 81 mg (low-dose group), and 7,242 patients received 325 mg aspirin (high-dose group). Complications tracked within 90 days after surgery were VTEs (DVT and PE), bleeding events

(gastrointestinal and wound bleeding) and mortality.

LOW-DOSE ASPIRIN IS NOT INFERIOR TO A HIGHER DOSE OF ASPIRIN IN THE PREVENTION OF VTE FOLLOWING TOTAL HIP AND KNEE ARTHROPLASTY.

## Aspirin use in THA

For patients who underwent total hip arthroplasty (THA), no statistically significant differences were observed between the aspirin groups in terms of VTE, DVT, PE, bleeding risk or mortality (Figures 1

and 2). After adjusting for confounders, low-dose versus high-dose aspirin was not associated with increased risk for VTE, DVT, PE, bleeding or mortality after THA.

## Aspirin use in TKA

For patients who underwent total knee arthroplasty (TKA), there were no statistically significant differences between the groups in terms of VTE, PE, bleeding or mortality after surgery (Figures 3 and 4). However, the incidence of DVT was lower in the low-dose aspirin group compared with the high-dose group (0.53 percent versus 1.41 percent, respectively,  $P = 0.01$ ). Interestingly, low-dose aspirin was associated with reduced risk of DVT compared with high-dose aspirin in the regression model after accounting for confounders (odds ratio = 0.38, 95 percent confidence interval [0.17 – 0.84],  $P = 0.006$ ). In addition, low-dose versus high-dose aspirin was not associated with increased risk of VTEs ( $P = 0.10$ ), PE ( $P = 0.17$ ), bleeding ( $P = 0.79$ ) or mortality ( $P = 0.78$ ) within 90 days after TKA.

## Physician takeaways from this study

Overall, there were no differences in VTE incidence following TKAs/THAs in low- versus high-dose aspirin groups. Both aspirin regimens showed similar results in terms of risk of bleeding (gastrointestinal and wound) and mortality after TJA.

We concluded that low-dose aspirin (81 mg twice a day) is not inferior to higher-dose aspirin (325 mg twice a day) in the prevention of VTE following total hip and knee arthroplasty. We currently use aspirin 81 mg PO BID for four weeks in primary arthroplasty procedures in low-risk patients.

*Dr. Higuera Rueda is Vice Chair for Quality and Patient Safety for the Orthopaedic & Rheumatologic Institute and Research Director for the Center for Adult Reconstruction. Dr. Faour is a clinical research fellow.*

Figure 1

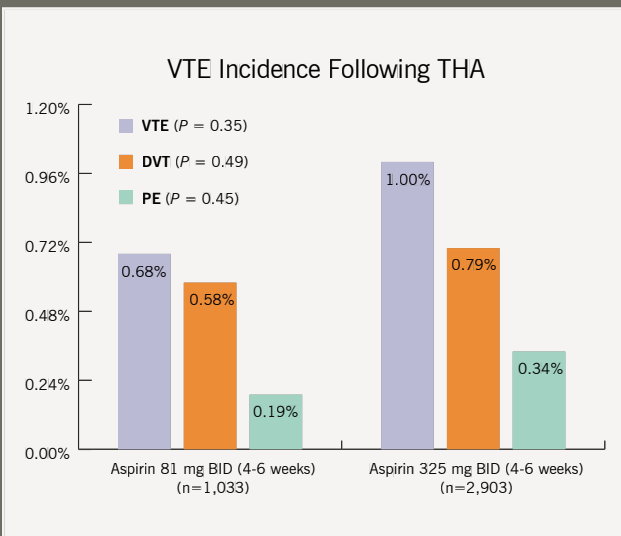


Figure 2

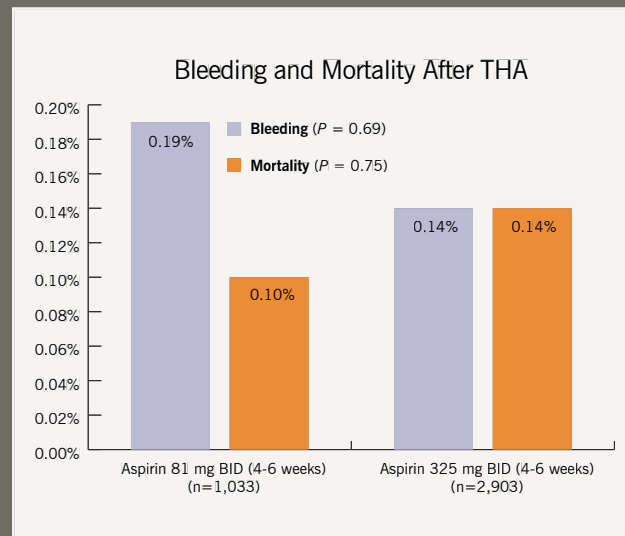


Figure 1

Incidence of venous thromboembolism, deep venous thrombosis and pulmonary embolism within 90 days after total hip arthroplasty.

Figure 2

Incidence of bleeding (gastrointestinal and wound) and mortality within 90 days after total hip arthroplasty.

Figure 3

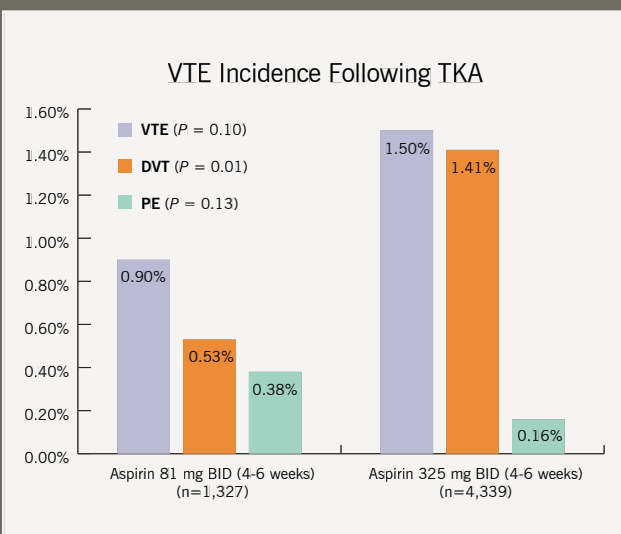


Figure 4

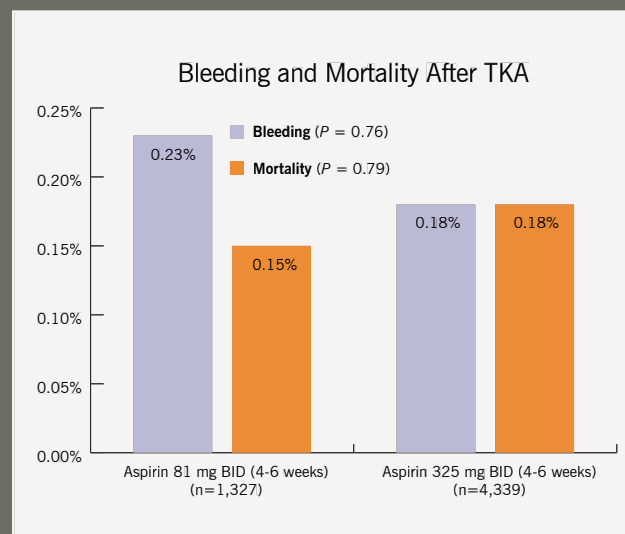


Figure 3

Incidence of venous thromboembolism, deep venous thrombosis and pulmonary embolism within 90 days after total knee arthroplasty.

Figure 4

Incidence of bleeding (gastrointestinal and wound) and mortality within 90 days after total knee arthroplasty.

# ANATOMIC MEDIAL PATELLOFEMORAL LIGAMENT RECONSTRUCTION CAN BE SAFELY PERFORMED IN THE SKELETALLY IMMATURE KNEE

## NEW TOOLS DEVELOPED TO TREAT RECURRENT PATELLOFEMORAL INSTABILITY, A COMMON PROBLEM



Lutul D. Farrow, MD, FAOA  
farrowl@ccf.org  
216.518.3620

Recurrent patellofemoral instability is quite common. Following an index patellar dislocation, the rate of recurrent dislocation is estimated to be 15 to 44 percent. Recurrent patellofemoral instability can be intermittently debilitating for patients when nonoperative measures fail. First-line treatment typically includes activity modification, physical therapy and bracing. When nonoperative management fails, surgical intervention may be warranted to prevent further patellofemoral dislocations.

Surgical management of this problem has been clearly defined in the skeletally mature knee. Due to the presence of open growth plates at the proximal tibia and distal femur, surgery in the skeletally immature knee can be technically challenging in order to avoid iatrogenic injury to the distal femoral physis. Through anatomic and radiographic investigation, we have provided several tools to assist surgeons with safe patellofemoral stabilization in the skeletally immature knee.

### An evolution in the treatment paradigm

Historically, nonanatomic soft tissue procedures and osteotomies were used to address recurrent patellofemoral instability. These procedures commonly caused osteoarthritis as a result of increased patellofemoral joint contact pressures.

More recently, the medial patellofemoral ligament (MPFL) has been identified as the major soft tissue restraint to lateral patellar dislocation (60 percent of cases). With this improved understanding, interest has grown in using MPFL repair and reconstruction to address refractory patellar instability, and the procedure has proved successful.

### Need for a better method for skeletally immature patients

A key step in the procedure is correct anatomic placement of the MPFL femoral tunnel. Schottle described a radiographic method of localizing the femoral footprint of the MPFL on a lateral radiographic image, based on several radiographic landmarks. Although Schottle's method has been shown to be reproducible in the adult population, it has never been validated in the pediatric population. The distal femoral physis has a complex, undulating anatomy that makes extrapolation of this technique to the pediatric population difficult. Using Schottle's method, Shea et al<sup>1</sup> incorrectly concluded that the MPFL femoral footprint was proximal to the distal femoral physis.

To address this issue, we studied and outlined difficulties using Schottle's method in the skeletally immature knee.<sup>2</sup> Subsequently, we demonstrated that there is considerable interobserver variation in approximating the MPFL femoral

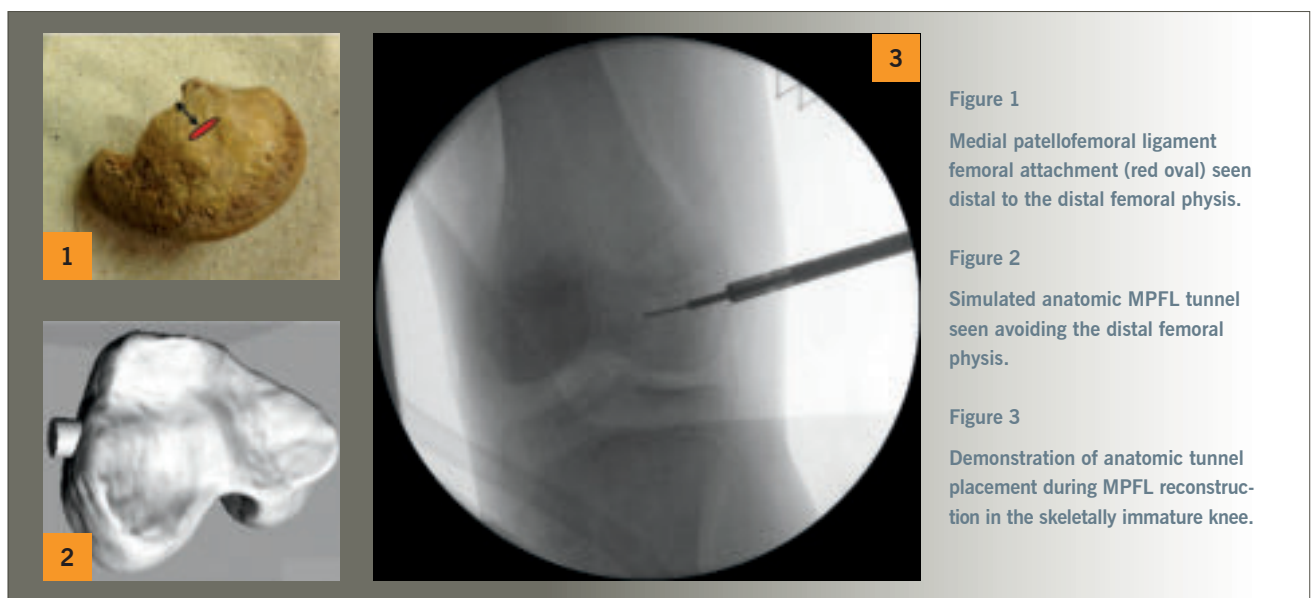


Figure 1  
Medial patellofemoral ligament femoral attachment (red oval) seen distal to the distal femoral physis.

Figure 2  
Simulated anatomic MPFL tunnel seen avoiding the distal femoral physis.

Figure 3  
Demonstration of anatomic tunnel placement during MPFL reconstruction in the skeletally immature knee.

tunnel utilizing this method in the skeletally immature knee. Use of this method alone can place the distal femoral physis at risk.

### Anatomic research provides guidance for surgeons

Adding to the difficulty of anatomic MPFL reconstruction in the skeletally immature knee, the MPFL femoral footprint is very close to the distal femoral physis. We have previously shown that the MPFL femoral footprint is situated<sup>3</sup> just 8.5 mm distal to the distal femoral physis (Figure 1).

Accurate placement of the MPFL is extremely important, as iatrogenic injury to the growth plate could result in growth arrest and subsequent angular deformity of the distal femur.

The findings of our anatomic study show that the MPFL footprint is far enough distal to the femoral growth plate to allow placement of an anatomic femoral tunnel without putting the physis at risk.

Furthermore, we have also described a safe zone for femoral tunnel placement<sup>4</sup> in the skeletally immature knee. By drilling the femoral tunnel at an angle of 15 to 20 degrees distal and anterior from the MPFL femoral footprint, surgeons can minimize risk<sup>4</sup> to the distal femoral physis, intercondylar notch and distal articular cartilage of the femur (Figure 2).

WE HAVE PROVIDED SEVERAL TOOLS TO ASSIST SURGEONS WITH SAFE PATELLOFEMORAL STABILIZATION IN THE SKELETALLY IMMATURE KNEE.

### Bringing it all together

Successful anatomic reconstruction of the MPFL can be accomplished with careful femoral tunnel starting point localization on both anteroposterior and lateral radiographic images, by understanding the anatomic location of the MPFL femoral footprint and by using the described safe zone for MPFL femoral tunnel drilling (Figure 3).

*Dr. Farrow serves as Program Director for the Orthopaedic Surgery Sports Medicine Fellowship.*

### References

1. Shea KG, Grimm NL, Belzer J, Burks RT, Pfeiffer R. *The relation of the femoral physis and the medial patellofemoral ligament.* Arthroscopy. 2010;26(8):1083-1087.
2. Huston KL, Okoroafor UC, Kaar SG, Wentt CL, Saluan PM, Farrow LD. *Evaluation of Schottle's method in the pediatric knee.* Orthop J Sports Med. 2017;5(11):2325967117740078.
3. Farrow LD, Alentado VJ, Abdulnabi Z, Gilmore A, Liu RW. *The relationship of the medial patellofemoral ligament attachment to the distal femoral physis.* Am J Sports Med. 2014;42(9):2214-2218.
4. Nguyen CV, Farrow LD, Liu RW, Gilmore A. *Safe drilling paths in the distal femoral epiphysis for pediatric medial patellofemoral ligament reconstruction.* Am J Sports Med. 2017;45(5):1085-1089.

# SCAPULAR NOTCHING FOLLOWING REVERSE TOTAL SHOULDER ARTHROPLASTY



Joel Kolmodin, MD  
kolmodj@ccf.org



Iyoo U. Davidson, MD  
davidsi@ccf.org



Bong-Jae Jun, PhD  
junb@ccf.org  
216.445.3577



Nipun Sodhi, MD  
sodhin2@ccf.org



Naveen Subhas, MD  
subhasn@ccf.org  
216.445.9464

## INVESTIGATING PATIENT-SPECIFIC BONY ANATOMY, IMPLANT LOCATION AND SHOULDER MOTION TO AVOID SCAPULAR NOTCHING

In a recent study that we conducted of patients who underwent a reverse total shoulder arthroplasty (rTSA), we found that areas of bony impingement on shoulder range of motion (ROM) matched the areas of radiographic scapular notching that develop postoperatively. This relationship was demonstrated using 3-D computed tomography (CT) kinematic simulation of patients' actual implant position from CT and actual postoperative ROM from video motion analysis (VMA). This connection between impingement and notching, while implied in prior studies, has not previously been directly shown in a clinical population.

### Scapular notching frequent after rTSA

Scapular notching is frequently observed following rTSA, although its etiology is not well-understood. It has been suggested that prosthesis design, scapular anatomy and implant position are responsible for this problem. Studies have used cadaver models, finite element analysis, computer modeling and retrospective radiographic review to examine either factors that influence impingement-free shoulder ROM following rTSA or factors associated with postoperative radiographic scapular notching. But the connection between impingement and notching has not been investigated directly.

The purpose of our study was to determine whether patient-specific postoperative shoulder ROM and bony impingement of the humeral component along the scapular neck on 3-D CT imaging analysis are predictive of the presence and location of radiographic notching that develops following rTSA. We also evaluated patient and prosthetic factors associated with scapular notching and changes in implant position needed to avoid patient-specific bony impingement.

### Study design

Thirty patients with preoperative CT scans who underwent rTSA were evaluated at minimum two-year follow-up with VMA, postoperative 3-D CT with metal artifact reduction techniques and standard radiographs. Reflective markers were placed on each patient's skin at specific bony prominences on the forearm, arm, scapula and thorax to perform VMA of patients' shoulder ROM during active abduction/

adduction and internal rotation/external rotation with the arm at the side. Glenohumeral ROM was then determined for each patient from VMA. This information was then combined with postoperative implant location from 3-D CT in custom 3-D CT kinematic simulation software to determine areas of bony impingement between the humeral implant and scapula (Figure 1).

The presence of impingement was correlated with the presence of scapular notching on postoperative CT and plain radiographs. We also investigated translational (lateral, inferior and posterior) and rotational (i.e., version and inclination) modifications to glenosphere position that eliminated bony impingement.

### Correlating impingement and postoperative notching

Seventeen patients had evidence of scapular notching on CT and/or plain radiographs at a minimum two-year follow-up. All had evidence along the posteroinferior scapular neck (Figure 2) and three along the anteroinferior neck. Bony impingement was observed during 3-D CT kinematic simulation of patients' glenohumeral ROM with external rotation and the arm at the side in 16 out of 17 patients, with internal rotation and the arm at the side in three of 17 patients, and with adduction and neutral rotation when moving through the abduction-adduction arc in 12 of 17 patients. The remaining 12 patients who underwent VMA did not have scapular notching or bony impingement. Bony impingement in the 3-D CT simulation was significantly associated with the presence of postoperative notching ( $P < 0.001$ ), and the location of impingement matched the location of notching on postoperative CT in all patients.

In evaluating factors associated with scapular notching, patients with notching had significantly greater preoperative glenoid retroversion (mean  $-17.4 \pm 14.2^\circ$  versus  $-7.7 \pm 10.4^\circ$ ,  $P = 0.04$ ) than patients without notching. Insufficient inferior (mean  $-0.3 \pm 3.4$  mm versus  $2.8 \pm 2.9$  mm,  $P = 0.015$ ) or posterior (mean  $-0.3 \pm 3.5$  mm versus  $3.8 \pm 2.6$  mm,  $P = 0.002$ ) glenosphere placement was also associated with scapular notching. On multivariate analysis, combined inferior and posterior (C-index 0.864,  $P = 0.0014$ ) or inferior and lateral (C-index 0.860,  $P = 0.0015$ ) glenosphere position was significantly different



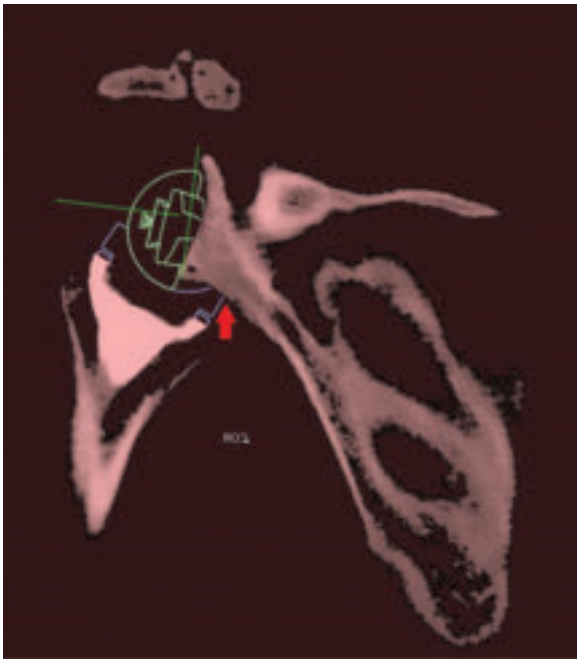


Figure 1

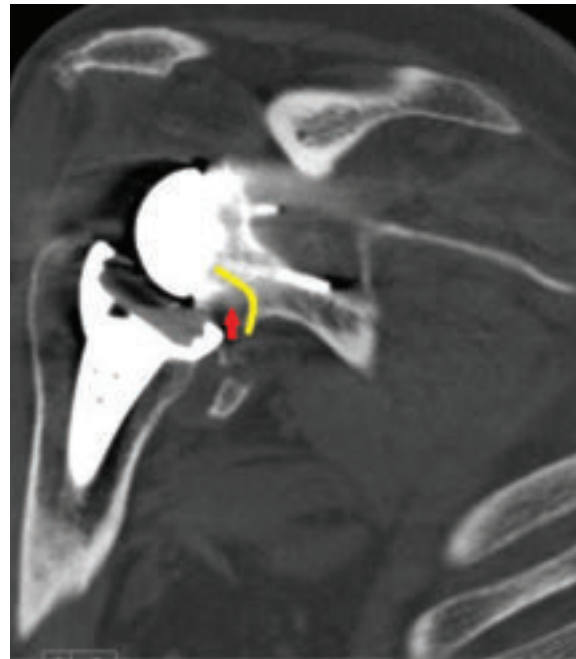


Figure 2



Thomas Patterson, PhD  
pattert@ccf.org  
216.444.5530



Zong-Ming Li, PhD  
liz4@ccf.org  
216.444.1211



Joseph P. Iannotti, MD, PhD  
iannotj@ccf.org  
216.445.5151



Eric T. Ricchetti, MD  
ricchee@ccf.org  
216.445.6915

#### Figure 1

Digital templates for the humeral and glenoid components were aligned with actual component positions on postoperative CT. Postoperative glenoid implant position was then registered to the preoperative CT using an image overlay technique available in the 3-D imaging software, such that the position and orientation of the glenoid component digital template on the postoperative scapula was transferred to the preoperative scapula, as shown in Figure 1. The postoperative humerus and the position and orientation of the humeral component digital template were mated to the preoperative scapula with postoperative glenoid component digital template as part of

the overlay technique. During 3-D CT kinematic simulation of patients' glenohumeral ROM, an automated detection method within the custom-designed 3-D imaging software detects impingement between the humeral component and the scapular neck, shown by the red arrow in the figure.

#### Figure 2

Evidence of scapular notching along the posteroinferior scapular neck, observed on a postoperative CT scan and shown by the red arrow, with the notched scapula outlined in yellow.

between the notching and non-notching groups. For patients' given ROM, placing the glenosphere in a more inferior (mean  $3.4 \pm 2.3$  mm) or lateral position (mean  $6.2 \pm 1.4$  mm) would have most avoided impingement in those who demonstrated impingement on 3-D CT kinematic simulation.

#### Conclusions and guidance on how to avoid notching

Our results demonstrate the connection between bony impingement and postoperative radiographic scapular notching in patients who have undergone rTSA. Notching is a 3-D phenomenon that appears to develop from bony impingement along the posteroinferior scapular neck and occurs most commonly from external rotation with the arm at the side.

Inferior and/or lateral or posterior glenosphere placement was found to be an important factor for avoiding notching. While posterior glenosphere position, relative to inferior and lateral placement, has not been commonly discussed as

important in avoiding notching, its importance is supported by the observation of the posteroinferior scapular neck being the most common site of notching and impingement.

Glenosphere position can be modified to avoid bony impingement with only small changes, suggesting that preoperative determination of ideal implant position based on patient-specific bony anatomy and kinematic ROM criteria may be a helpful surgical planning tool to avoid notching postoperatively.

*Drs. Kolmodin and Davidson are residents; Dr. Sodhi is a research fellow; Drs. Jun and Patterson are researchers; Dr. Subhas is on staff in the Radiology Department; Dr. Li is on staff in the Biomedical Engineering Department; Dr. Iannotti is the institute Chair; and Dr. Ricchetti is Director of the Shoulder Center.*

# WHY DO BUNION SURGERIES FAIL?

## WHILE CAUSES ARE MULTIFACTORIAL, GOOD SURGICAL DECISION-MAKING AND TECHNIQUE REDUCE FAILURES



Mark J. Berkowitz, MD  
berkowm@ccf.org  
440.260.3731

Hallux valgus is a common forefoot ailment that frequently requires surgical intervention when nonsurgical management fails to provide symptomatic relief. Unfortunately, bunion surgeries can fail in a number of ways, often leaving the patient with more pain, persistent deformity, and marked dissatisfaction and dysfunction. The question is: “Why do bunion surgeries fail?”

### Patient and surgical factors come into play

The cause of recurrent hallux valgus is usually multifactorial and includes patient-related and surgical factors. Patient-related factors include medical comorbidities such as obesity and osteopenia, as well as noncompliance with postsurgical weight-bearing restrictions. Skeletal immaturity, generalized ligamentous laxity, neuromuscular conditions, smoking and continued use of poorly fitting shoes also can contribute to failure.

While patient-related factors individually and collectively increase the risk for complications, the majority of failed bunion surgeries result from surgeon error — either technical or in surgical decision-making.

Essentially, bunion surgeries can fail in the following circumstances:

- The deformity is not fully corrected and hallux valgus persists or recurs.
- The deformity is overcorrected into varus.
- The bone doesn't heal, resulting in a nonunion.
- The bone heals in the wrong position, creating a malunion.

### Undercorrection

Surgeons select the appropriate procedure preoperatively based on clinical and radiographic evaluations of the individual deformity. By choosing an underpowered procedure, a surgeon may not be able to fully correct the deformity, leading to recurrence of the hallux valgus. For instance, internal fixation methods have expanded the range of deformities distal procedures can address. Yet in general, it is still well-accepted that larger deformities with elevated intermetatarsal angles (IMAs) are best treated with proximal

procedures. Failure to correct the IMA to less than 10 degrees is a marked risk for undercorrection and/or recurrence of deformity (Figures 1A-C).

A less obvious cause of undercorrection and recurrence is failure to appreciate and correct an elevated distal metatarsal articular angle (DMAA). This angle indicates how laterally the first metatarsophalangeal joint (MTPJ) is oriented. Ultimately, the final hallux valgus angle after bunion surgery will approximate the DMAA. Thus, if it is not corrected to less than 10 degrees, significant residual deformity or recurrence will occur. Choosing an osteotomy that specifically addresses and diminishes the DMAA provides the best opportunity for adequate and durable correction (Figures 2A-B).

### Overcorrection

Overcorrection of hallux valgus deformities is less common than undercorrection, but arguably results in greater symptoms and dissatisfaction. Whereas undercorrection often is

THE MAJORITY OF  
FAILED BUNION  
SURGERIES RESULT  
FROM SURGEON  
ERROR — EITHER  
TECHNICAL OR IN  
SURGICAL DECISION-  
MAKING.

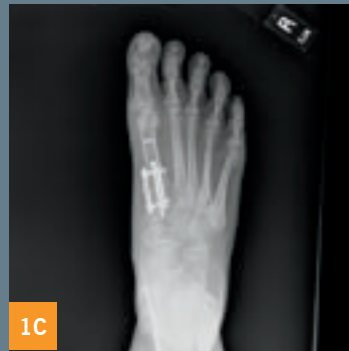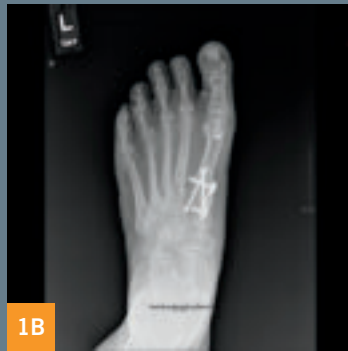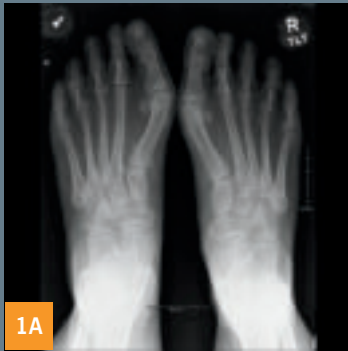the result of faulty surgical decision-making, overcorrection generally results from surgeon technical error.

Technical errors include a too aggressive lateral soft-tissue release or an overly aggressive resection of the medial eminence. Similarly, if the intermetatarsal angle

is overcorrected, a hallux varus deformity may gradually develop (Figure 3). Many cases of postoperative hallux varus are symptomatic enough to require revision surgery, which can take the form of first MTPJ fusion or reconstruction.

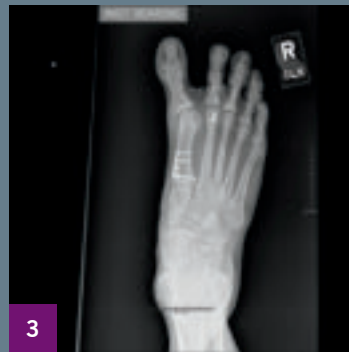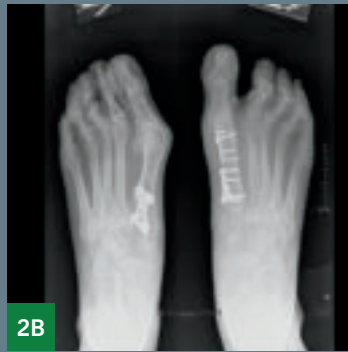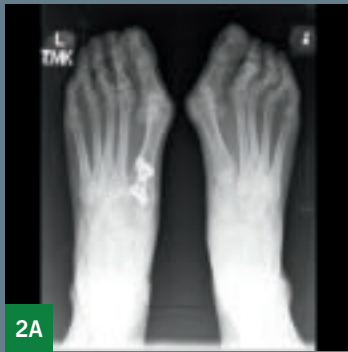### Nonunion and malunion

First metatarsal osteotomies can be challenging to fix adequately due to the relatively small size of the bone and



Figures 1A-C

Radiographs of 68-year-old female one year after bilateral bunion surgeries with residual deformity. Note the persistently elevated IMA. Each foot was subsequently revised using the Lapidus procedure.



Figures 2A-B

Radiographs of 60-year-old female who experienced gradual recurrence of left bunion even after aggressive correction of IMA with Lapidus procedure. Note the elevated DMAA. When the right foot was surgically treated, both IMA and DMAA were corrected using a double osteotomy, resulting in excellent and durable correction of deformity.

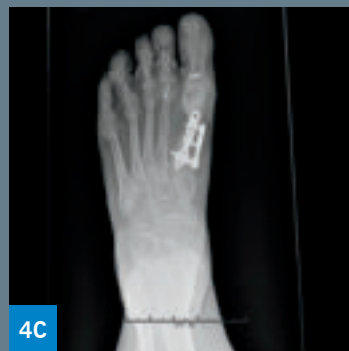
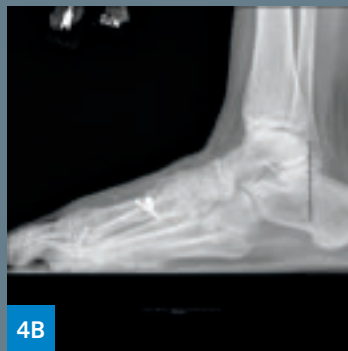
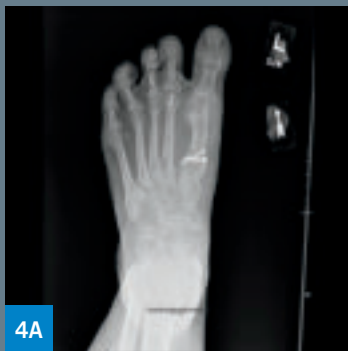Figure 3

Radiograph of 58-year-old female demonstrates hallux varus after overcorrection of the IMA.

Figures 4A-C

Radiographs of 57-year-old female with hallux varus and dorsiflexed malunion of a proximal first metatarsal osteotomy. Successful revision was achieved with first MTPJ reconstruction, correction of the malalignment, bone grafting and aggressive internal fixation.

limited area available for fixation. If osteopenia is present, the patient is noncompliant with weight-bearing restriction or technical errors are made in creating or fixing the osteotomy, nonunion and/or malunion can develop. Nonunion of first metatarsal osteotomies produces pain at the nonunion site. Nonunion is also associated with dorsiflexion malposition, which transfers stress to the lesser metatarsals, resulting in transfer metatarsalgia. Transfer metatarsalgia also can occur if the osteotomy heals in a dorsiflexed position.

Nonunions and malunions of osteotomies used for bunion correction are almost always symptomatic and require revision with repeat osteotomy, bone grafting and revision fixation (Figures 4A-C).

**The solution: Preoperative planning and meticulous surgical technique**

Bunion surgery remains a technically challenging procedure, and patients have high expectations in terms of deformity correction and functional outcome. Undercorrection, overcorrection, nonunion and malunion remain the most common causes of failed bunion surgery. Although patient factors definitely contribute to disappointing outcomes, most failures are the result of poor surgical decisions and/or poor surgical technique.

Diligent preoperative evaluation and surgical planning combined with meticulous surgical technique will minimize these complications and provide patients with the outcome they desire.

*Dr. Berkowitz is Director of the Foot and Ankle Center in the Department of Orthopaedic Surgery.*

# VERTEBRAL BODY RESECTION FOR SEVERE CONGENITAL KYPHOSIS

## HIGH-MAGNITUDE CURVES POSE CHALLENGES, BUT AS THIS CASE STUDY DEMONSTRATES, EXPERIENCE CAN YIELD SUCCESS



R. Douglas Orr, MD  
orrd@ccf.org  
216.363.2410

C.R. presented to Cleveland Clinic at age 27 complaining of predominantly axial back pain. She had a known congenital kyphosis of the thoracolumbar junction that had been followed for many years at another hospital. Over approximately two years she developed debilitating back pain and some activity-related bilateral lower-extremity pain.

Examination, including anteroposterior and lateral X-rays (see Figure 1), confirmed a severe congenital kyphosis (130 degrees) at the thoracolumbar junction, lumbar hyperlordosis and thoracic hyperlordosis.

### Challenges and surgical plan

High-magnitude curves such as this present many challenges for surgical treatment. The bony anatomy is altered due to the underlying congenital anomalies as well as the adaptive changes that have occurred over years in such an abnormal posture. In addition, the spinal cord is tightly opposed to the vertebral bodies at the apex.

The surgical plan was an all-posterior approach with resection of the abnormal vertebra at the apex of the kyphosis and a long segmental instrumentation. This procedure is called a vertebral body resection and essentially results in separation of the spinal column into two mobile segments with only the dura and spinal cord staying intact across the ensuing defect.

Difficulties were anticipated in removing the vertebral body with the cord in such proximity. In cases like

this it is also difficult to determine the optimal length of the spinal column after resection. If the spine is shortened too much, there can be kinking of the spinal cord, leading to a spinal cord injury. If the column is lengthened too much, stretching of the cord can result and likewise lead to neurologic injury. Placement of hardware is also difficult, given the abnormal trajectories for pedicle screws involved.

### A role for intraoperative monitoring

The use of intraoperative spinal cord monitoring with somatosensory and motor evoked potentials greatly assists the surgeon in safely resecting the vertebral body and restoring spinal alignment without compromising spinal cord function. In a case such as this, the ability to obtain an intraoperative CT scan and merge it with an image-guided navigation system makes it much easier to place instrumentation while also helping guide the surgeon in complete resection of the

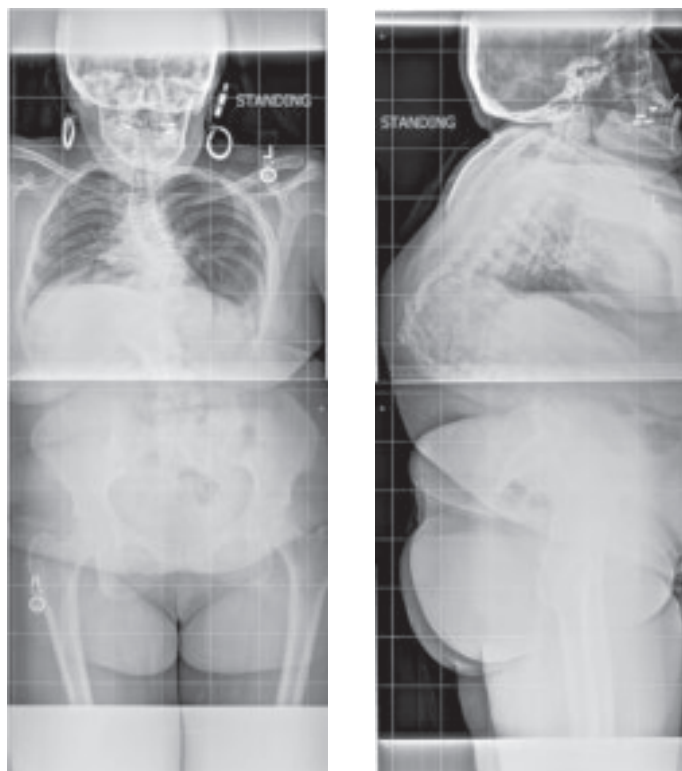
vertebral bodies across the apex. The anterior column is then reconstructed with an expandable interbody cage and long-segment posterior instrumentation.

### Surgery and postoperative course

Figure 2 shows an intraoperative lateral X-ray from this patient's case with a combination of temporary and definitive hardware in position. The surgery took about 8.5 hours.

At her most recent follow-up, six months after surgery, the patient was almost completely pain-free, had returned to full

**Figure 1**  
The patient's preoperative standing X-rays. The anteroposterior view (left) shows some coronal plane deformity. The lateral view (right) shows a 130-degree congenital kyphosis.



**Figure 1**

unrestricted activities and reported being very happy with her clinical status. Figure 3 shows her X-rays taken at that time.

Surgeries for high-magnitude spinal deformities are among the most complex and challenging that can be performed. They are best done at centers with a large experience in these types of operations and access to a wide variety of advanced surgical techniques. Although these procedures carry relatively high risks, when successful, they can result in major improvements in a patient's quality of life.

ALTHOUGH THESE PROCEDURES CARRY RELATIVELY HIGH RISKS, WHEN SUCCESSFUL, THEY CAN RESULT IN MAJOR IMPROVEMENTS IN A PATIENT'S QUALITY OF LIFE.

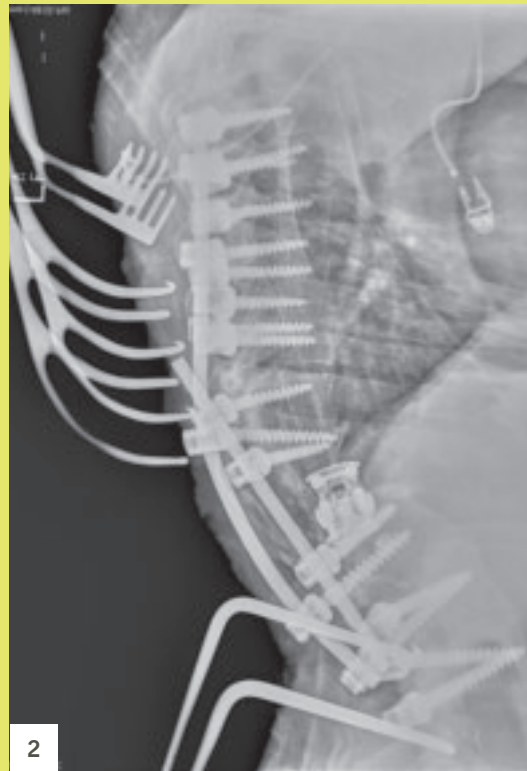

Figure 2

Intraoperative lateral X-ray showing a combination of temporary and definitive hardware after initial correction of the deformity.

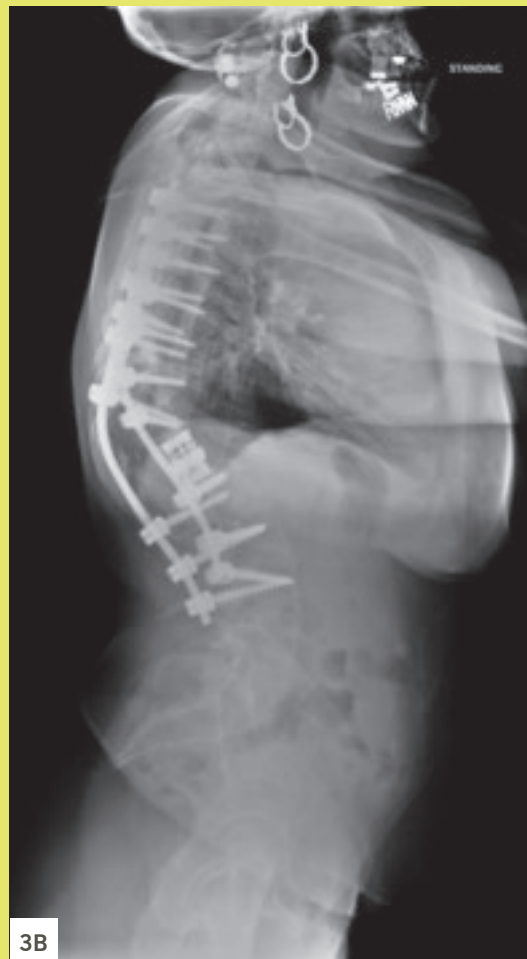
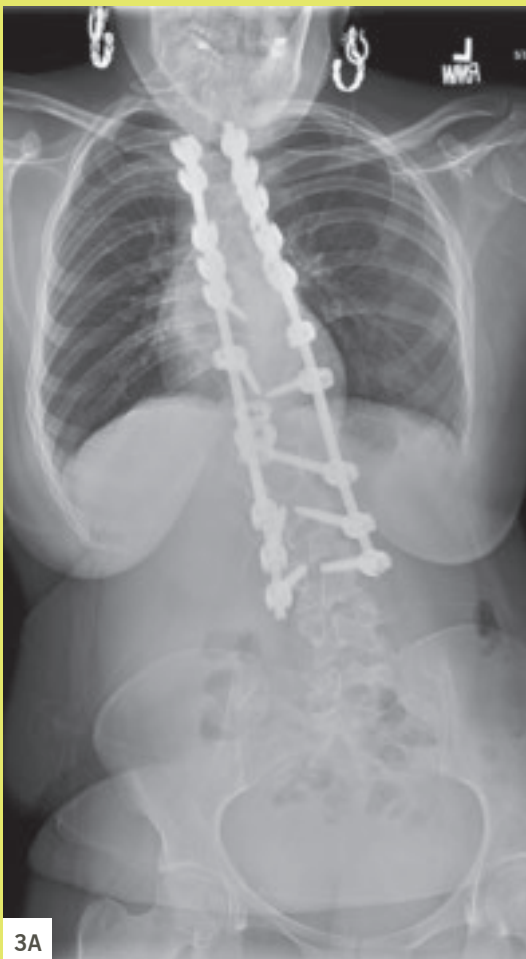

Figure 3

X-rays taken six months postoperatively. The anteroposterior image (3A) shows some persistent coronal plane malalignment, while the lateral image (3B) shows the final hardware construct and good sagittal alignment.

*Dr. Orr is a spine surgeon in Cleveland Clinic's Center for Spine Health.*

# THE IMPACT OF NEUROMUSCULAR QUADRICEPS STIMULATION ON TOTAL KNEE REPLACEMENT OUTCOMES

## STUDY EXAMINES PRE- AND POSTOPERATIVE BENEFITS



Gary J. Calabrese, PT, DPT  
calabrg@ccf.org  
216.445.3461

Postoperative quadriceps muscle weakness coupled with muscle atrophy contributes to impaired knee function following knee surgery. Similarly, patients with knee osteoarthritis (OA) have characteristically demonstrated quadriceps muscle weakness leading to reduced ability to generate force, and thus compromised function.

Unfortunately, there is a paucity of research studying the effects of rehabilitation methods to combat these deficits. This includes the use of neuromuscular electrical stimulation (NMES) to enhance quadriceps strength. NMES has not been well-studied for knee surgeries other than in postoperative anterior cruciate ligament reconstruction rehabilitation.

To address this lack of data, Cleveland Clinic's Orthopaedic & Rheumatologic Institute has designed a study to assess applying NMES to the quadriceps in the preoperative and postoperative phases of a total knee replacement care algorithm. Our hypothesis is that using NMES both pre- and postoperatively can improve functional outcomes following total knee replacement (TKR).

The current standard for rehabilitation after TKR consists of guided exercise therapy for up to 12 weeks. This includes inpatient, home and outpatient therapy. The surgery and rehabilitation are highly successful at reducing or eliminating pain experienced preoperatively. However, quadriceps femoris muscle (QFM) strength, overall function, and knee range of motion are often worse than preoperative levels for as long as six months after surgery and in some cases for many years. Such quadriceps muscle strength impairments after TKR have been largely attributed to voluntary activation deficits and can lead to diminished functional performance such as decreased gait speed, decreased balance that can lead to falls, and decreased stair-climbing and chair-rise abilities.

### Prehabilitation benefits of NMES?

It has previously been shown that preoperative QFM strength is predictive of postoperative function, but the benefit of prehabilitation remains in question. To date, only one pilot study has assessed the benefits of NMES when initiated preoperatively. This study included only 14 patients (nine NMES, five control), but demonstrated that preopera-

tive NMES usage may lead to greater QFM strength gains after TKR.

### Postoperative NMES: Timing is key

Since physical therapy alone does not adequately restore or improve upon preoperative functional capabilities in a consistent and timely manner, it has been suggested that NMES used adjunctively with postoperative rehabilitation will alleviate quadriceps muscle activation deficits. Early NMES use after TKR has the potential to reduce knee extensor lag and increase walking speed, as well as improve QFM strength, knee range of motion and function. However, NMES initiated one month after TKR did not lead to improved QFM strength or function beyond the standard benefits gained from exercise alone, thus suggesting that the timing of NMES application after TKR is important.

The specific aims of our study are to assess:

- Whether patients treated with pre- and postoperative NMES show improved physical performance and functional measures when compared with a postoperative-only NMES group and a standard-of-care group.
- If NMES patients show improved patient-reported outcomes.
- Whether patients treated with NMES require fewer outpatient physical therapy visits, fewer discharge dispositions to extended care facilities, shorter lengths of stay in extended care facilities, decreased 90-day postoperative readmission rates and decreased dependencies on ambulatory assist devices.

The challenges for current rehabilitation programs is that most do not address quadriceps muscle activation deficits in the first two to four weeks after TKR. Instituting exercise programs that stress strong quadriceps muscle contractions utilizing NMES — both before and after surgery — to facilitate muscle activation can help improve the preoperative strength baseline and may help reverse quadriceps weakness in patients who have knee osteoarthritis that has been reported to worsen after surgery.

*Dr. Calabrese is Senior Director, Cleveland Clinic Rehabilitation and Sports Therapy.*

# RESIDENCY UPDATE

## 2017

### IT'S "DAYS OF FUTURE PASSED" FOR ORTHOPAEDIC SURGERY RESIDENTS

"Shoot," I said, one Saturday morning a few months back while perusing the entertainment section of the increasingly cachectic *Cleveland Plain Dealer*.

"What's wrong?" said the voice at the opposite end of the breakfast table.

"The Moody Blues are in town. I would have liked to have seen them again," I responded.

"So see if there are tickets on Stub Hub for less than a tuition payment."

"Say no more," I thought rather than said out loud, fearing it could be taken out of context. And in a moment of uncharacteristic spontaneity, I quickly secured two very decent and fairly priced seats to that evening's performance — a concert which would include, among other platinum hits, the entire *Days of Future Passed* album. And yes, it was a truly grand performance.

As a child of the '70s, I think that all of the Moody Blues album titles, *Days of Future Passed* included, are somewhat thought-provoking and, if you'll forgive me, quasi-profound. There is *In Search of the Lost Chord*, *A Question of Balance*, *Seventh Sojourn* and *To Our Children's Children's Children*, to name a few. They all conjure up the great questions, joys and conflicts of life. And it is with this profundity in mind and perhaps tongue in cheek that we turn our attention to reflect on the annual torch passing that occurs in residency programs each July.

#### Graduating from our main campus residency program

- **VAHID ENTEZARI, MD** – Now at Thomas Jefferson University Hospitals in Philadelphia for a shoulder and elbow fellowship with plans to return to Cleveland Clinic in 2018
- **PATRICK MARINELLO, MD** – At OrthoCarolina in Charlotte, doing a hand and upper extremity fellowship
- **DAN MESKO, DO** – Currently an adult reconstructive fellow at Rush University Medical Center in Chicago
- **MICHAEL SILVERSTEIN, MD** – Also at OrthoCarolina, but logging hours as a spine fellow

#### Graduating from our Cleveland Clinic South Pointe Hospital residency program

- **J. FREELAND ACKLEY, DO** – Now a spine fellow at Cleveland Clinic main campus.

- **CESAR CEREIJO, DO** – At Vanderbilt University Medical Center in Nashville doing a traumatology fellowship

Staying on the theme of "passed," I am happy to report the continued success of our graduates, all of whom passed their board exams earlier this summer.

#### Medical school graduates, eager to start the journey recently completed by the departed chiefs

At Cleveland Clinic main campus:

- **MORAD CHUGTAI, MD** – American University of Antigua College of Medicine
- **JESSICA CHURCHILL, MD** – Eastern Virginia School of Medicine
- **SANIA MAHMOOD, MD** – Drexel University College of Medicine
- **ERIN OHLIGER, MD** – Northeast Ohio Medical University
- **ALEX ROTH, MD** – University of Cincinnati College of Medicine
- **NICK SCARCELLA, MD** – Case Western Reserve University School of Medicine

At Cleveland Clinic South Pointe Hospital:

- **KEVIN BAILEY, DO** – Ohio University College of Osteopathic Medicine
- **MICHAEL FIRTHA, DO** – Campbell University School of Osteopathic Medicine, North Carolina
- **DANIEL KANA, DO** – Ohio University College of Osteopathic Medicine

And so the cycle continues, as the old gives way to the new, and change never stops. But be not forlorn about change. Rather think of one last Moody Blues album title: *On the Threshold of a Dream*. Are we not all on the threshold of something new that offers that same great potential facing our graduates? Let's hope so. Until the next cycle ...

*Dr. Kuivila, a pediatric orthopaedic and scoliosis surgeon, is Vice Chairman for Education in the Orthopaedic & Rheumatologic Institute and the Orthopaedic Surgery Residency Program Director at our main campus.*



Thomas Kuivila, MD  
kuivilt@ccf.org  
216.444.2741



# ORTHOPAEDIC INSIGHTS

WINTER 2018

## 24/7 Referrals

**855.REFER.123** (855.733.3712)  
[clevelandclinic.org/refer123](http://clevelandclinic.org/refer123)

### OUTCOMES DATA

View Outcomes books at  
[clevelandclinic.org/outcomes](http://clevelandclinic.org/outcomes)

### CME OPPORTUNITIES

Visit [ccfcme.org](http://ccfcme.org) for live and online offerings from Cleveland Clinic's Center for Continuing Education.



## Stay Connected with Cleveland Clinic's Orthopaedic & Rheumatologic Institute

### CONSULT QD – ORTHOPAEDICS

News, research and perspectives from Cleveland Clinic experts.  
[consultqd.clevelandclinic.org/topics/orthopaedics](http://consultqd.clevelandclinic.org/topics/orthopaedics)



[Facebook.com/CME ClevelandClinic](https://www.facebook.com/CME ClevelandClinic)



[@CleClinicMD](https://twitter.com/CleClinicMD)



[clevelandclinic.org/MDlinkedin](http://clevelandclinic.org/MDlinkedin)



[clevelandclinic.org/ortho](mailto:clevelandclinic.org/ortho)

Cleveland Clinic is an integrated healthcare delivery system with local, national and international reach. At Cleveland Clinic, more than 3,500 physicians and researchers represent 140 medical specialties and subspecialties. We are a main campus, more than 150 northern Ohio outpatient locations (including 18 full-service family health centers and three health and wellness centers), Cleveland Clinic Florida, Cleveland Clinic Lou Ruvo Center for Brain Health in Las Vegas, Cleveland Clinic Canada and Cleveland Clinic Abu Dhabi. In 2017, Cleveland Clinic was ranked the No. 2 hospital in America in *U.S. News & World Report's* "Best Hospitals" survey. The survey ranks Cleveland Clinic among the nation's top 10 hospitals in 13 specialty areas, and the top hospital in heart care (for the 23rd consecutive year) and urologic care.